



PATIENT

Mac Smith

PRESENTING CLINICAL SIGNS

Chronic hepatic enzymopathy with elevated post-prandial bile acids. Liver enzyme elevation was initially noticed 2 months ago on routine blood work with no concerns reported by the owner although it has been noted that he seems quieter than a normal puppy.

SPECIES

Canine

COMPUTED TOMOGRAPHY OF THE ABDOMEN

A pre- and post-contrast CT study of the abdomen in a bone and soft tissue reconstruction is provided for review.

BREED

Shih Tzu

COMPUTED TOMOGRAPHIC FINDINGS

The serosal fat presents normal attenuation behavior. There is no evidence of peritoneal effusion or peritonitis.

SEX

MN

Both kidneys present within normal limits for size, shape and organ architecture. After contrast administration a bilaterally symmetric and uniform nephro- and pyelogram is noted.

AGE

1 Year, 5 Months

The adrenal glands are within normal limits for size, shape and organ architecture.

Both liver and spleen present with normal shape, even surface, uniformly attenuating parenchyma and homogeneous contrast enhancement, unremarkable.

The portal vein presents a normal order of its tributary veins and intrahepatic branching. No abnormal vessel is noted inside and outside of the liver parenchyma.

INTERPRETED BY

Sebastian Schaub, DVM
Dr. med. vet. DipECVDI

The pancreas is evenly contoured, the pancreatic parenchyma is homogeneous and presents uniform contrast enhancement.

The position, delineation, wall and content of the gastrointestinal tract are considered within normal limits throughout.

HOSPITAL NAME

Animal Health
Partners

The bony and surrounding soft tissue structures reveal no abnormalities.

COMPUTED TOMOGRAPHIC DIAGNOSIS

- No evidence of portosystemic shunting, neither intra- nor extrahepatic

REFERRING VET

Dr. Debbir Reynolds

INTERPRETATION OF THE FINDINGS & FURTHER RECOMMENDATIONS

No macroscopic vascular bypass of the liver was noted in the pre- and post- contrast studies of the abdomen. However, if the clinical signs are consistent with insufficiency of the liver primary non-cirrhotic portal hypertension (microvascular dysplasia) or other diffuse parenchymal liver disease would still be a potential and should be ruled out by means of ultrasound guided or surgical liver biopsy.

INVOICE

55676

DATE

12-17-22



PATIENT

Mac Smith

SPECIES

Canine

BREED

Shih Tzu

SEX

MN

AGE

1 Year, 5 Months

INTERPRETED BY

Sebastian Schaub, DVM
Dr. med. vet. DipECVDI

HOSPITAL NAME

Animal Health
Partners

REFERRING VET

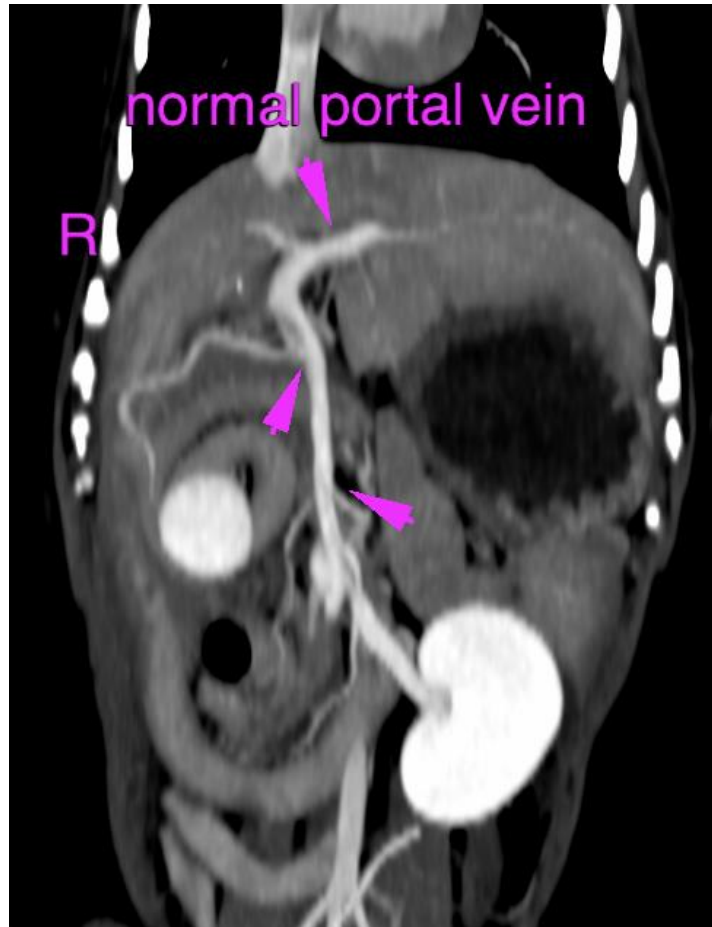
Dr. Debbir Reynolds

INVOICE

55676

DATE

12-17-22



The information and recommendations provided are based on the images presented by the referring veterinarian/sonographer. No evaluation can be communicated regarding pathology that was not visible in the image/video clips provided.

Thank you for this referral. If the clinical or image interpretation does not parallel your findings or if I can be of any further assistance please contact me.

Sebastian Schaub, Sebastian Schaub, DVM, Dr. med. vet. DipECVDI
sebast.schaub@gmail.com