


**PATIENT PRESENTING CLINICAL SIGNS**

Zuke Hahn Inappropriate urination for 5 days. Appetite and energy level both decreased for 2-3 days. Abnormal PE/Chem/CBC/UA Results: Muffled heart sounds. Urine is dilute (1.006), otherwise normal. CBC/chem pending.

**SPECIES RADIOGRAPHIC STUDY OF THE THORAX**

Canine Radiographs of the thorax in three imaging planes are provided for review.

**BREED RADIOGRAPHIC FINDINGS**

Border Collie X The surrounding bony structures are within normal limits.  
 The extrathoracic soft tissues present homogeneous without abnormalities.

**SEX** The heart is generalized moderately enlarged and presents a globoid shape. The pulmonary vessels are thin. The caudal vena cava is prominent.

Neutered Male

**AGE** The cranial mediastinum presents the expected soft tissue opacity. The mediastinal width is less than twice the width of the vertebral column at the same level.

9 Years The trachea is normal in diameter and presents the anticipated course. The luminal outline of the trachea is smooth.

**INTERPRETED BY**

Sebastian Schaub,  
 DVM Dr. med. vet.  
 DipECVDI

The bronchial tree presents with thin walls and tapers uniformly towards the periphery as expected. A pleural fissure line is visible between the right cranial & middle lung lobe. The lung parenchyma presents the expected architecture and opacity; the intrapulmonary vascular branching is seen up to the third order lung vessels.

The diaphragm is well delineated with even surface and the expected mild cranial bulging of the diaphragmatic cupola.

**HOSPITAL NAME**

Q Street AH

**RADIOGRAPHIC DIAGNOSIS**

- Cardiomegaly with globoid appearance and reduced size of the pulmonary vasculature
- Suspect very mild pleural effusion
- Prominent caudal vena cava

**REFERRING VET**

Dr. Phoebe Cone

**INTERPRETATION OF THE FINDINGS & FURTHER RECOMMENDATIONS**
**INVOICE**

33560

The cardiac changes in combination with the vascular findings are concerning for pericardial effusion with potential cardiac tamponade. Recommend cardiac echo to confirm the diagnosis and check for underlying neoplastic or inflammatory disease.

**DATE**

12/17/21



**PATIENT**

Zuke Hahn

**SPECIES**

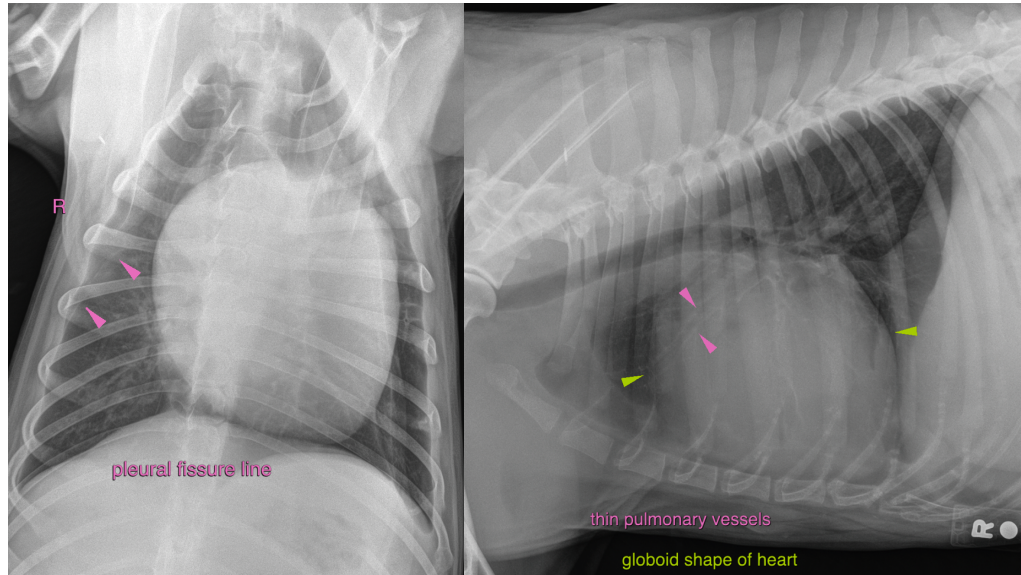
Canine

**BREED**

Border Collie X

**SEX**

Neutered Male



**AGE**

9 Years

The information and recommendations provided are based on the images presented by the referring veterinarian. No evaluation can be communicated regarding pathology that was not visible in the image/video clips provided.

**INTERPRETED BY**

Sebastian Schaub,  
DVM Dr. med. vet.  
DipECVDI

Thank you for this referral. If the clinical or image interpretation does not parallel your findings or if I can be of any further assistance please contact me.

**Sebastian Schaub**, Sebastian Schaub, DVM, Dr. med. vet. DipECVDI  
sebast.schaub@gmail.com

**HOSPITAL NAME**

Q Street AH

**REFERRING VET**

Dr. Phoebe Cone

**INVOICE**

33560

**DATE**

12/17/21