


PATIENT PRESENTING CLINICAL SIGNS

Leggo Lish-Dooley One month history of severe L-sided head tilt, possible seizure episodes. Anterior lens luxation OS and lens subluxation OD. OS enucleated 5/4/21
 Abnormal PE/Chem/CBC/UA Results: 11/19/21- nCBC/Chem WNL. 4Dx negative, T4= 1.5 (1-4).
 P,E,: L-sided head tilt.

SPECIES

Canine

COMPUTED TOMOGRAPHIC STUDY OF THE SKULL

A high resolution pre- and post-contrast CT study of the skull is provided for review.

BREED

Wire Haired Terrier

COMPUTED TOMOGRAPHIC FINDINGS

Triadan 311&411 are absent.

SEX

Intact Male

The left ocular bulb is absent. The lens of the right ocular bulb is partially displaced into the anterior chamber.

AGE

7 Years

Both tympanic bullae are aerated, the mucosal lining is not seen, the bony wall is smooth and thin. The external ear canals are within normal limits.

INTERPRETED BY

Sebastian Schaub,
 DVM Dr. med. vet.
 DipECVDI

The brain presents no deviation from normal anatomy and symmetry. The brain parenchyma is homogeneous and within normal limits for attenuation and distribution of contrast enhancement. The ventricular system is non-dilated and symmetric.

The submandibular and medial retropharyngeal lymph nodes are small and elongated with a normal short-to-long-axis-ratio is < 0.5, the attenuation and contrast enhancement pattern is uniform.

COMPUTED TOMOGRAPHIC DIAGNOSIS
HOSPITAL NAME

Healing Spirit

- Subluxation lens right ocular bulb
- History of enucleation left eye
- Structural normal brain
- No evidence of otitis media or interna

REFERRING VET

Dr. Desen Ertunc

INTERPRETATION OF THE FINDINGS & FURTHER RECOMMENDATIONS

The CT study of the skull presents without abnormalities, explaining the described head tilt. An ischemic insult of the central nervous system might be a consideration here. If there is strong clinical suspicion for structural changes of the brain, complementing workup by an MRI study can be considered.

INVOICE

33548

DATE

12/17/21



PATIENT

Leggo Lish-Dooley

SPECIES

Canine

BREED

Wire Haired Terrier

SEX

Intact Male

AGE

7 Years

INTERPRETED BY

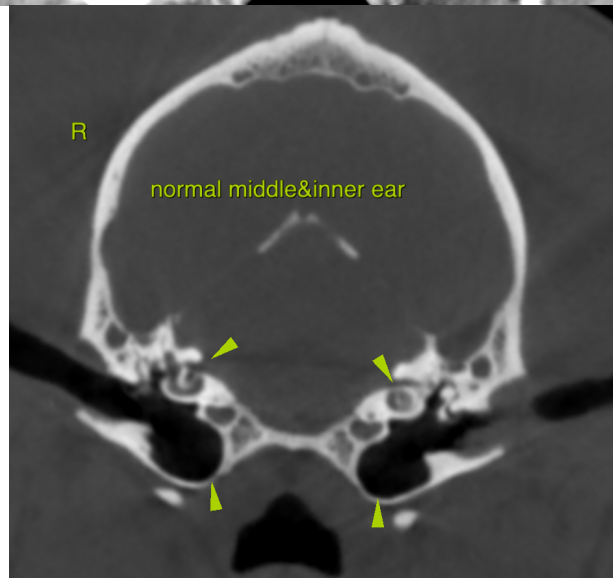
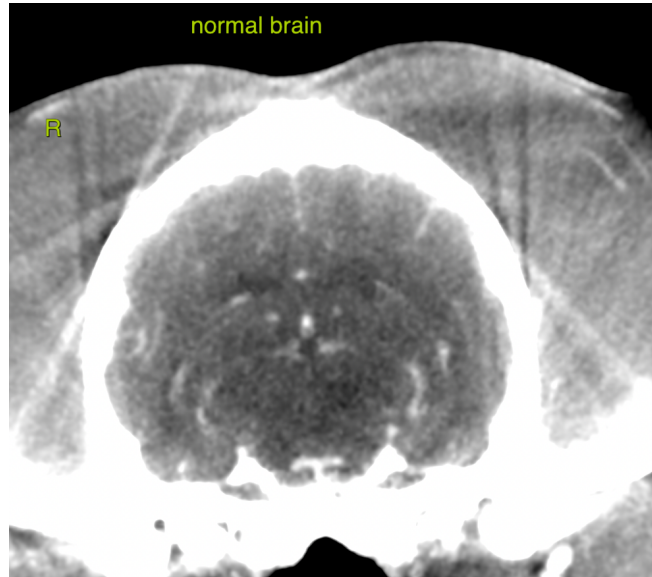
Sebastian Schaub,
DVM Dr. med. vet.
DipECVDI

HOSPITAL NAME

Healing Spirit

REFERRING VET

Dr. Desen Ertunc



The information and recommendations provided are based on the images presented by the referring veterinarian. No evaluation can be communicated regarding pathology that was not visible in the image/video clips provided.

INVOICE

33548

Thank you for this referral. If the clinical or image interpretation does not parallel your findings or if I can be of any further assistance please contact me.

DATE

12/17/21

Sebastian Schaub, Sebastian Schaub, DVM, Dr. med. vet. DipECVDI
sebast.schaub@gmail.com