
PATIENT PRESENTING CLINICAL SIGNS

Boone Retburg Murmur present and needs a neuter

RADIOGRAPHIC STUDY OF THE THORAX
SPECIES

Radiographs of the thorax in three imaging planes are provided for review.

Canine

RADIOGRAPHIC FINDINGS
BREED

The surrounding bony structures are within normal limits.

Cavalier King Charles

The extrathoracic soft tissues present homogeneous without abnormalities.

SEX

The heart is of normal size and shape, there is no evidence of cardiac chamber or vascular enlargement. The pulmonary vasculature is within normal limits.

Male

The cranial mediastinum presents the expected soft tissue opacity. The mediastinal width is less than twice the width of the vertebral column at the same level.

AGE

The trachea is normal in diameter and presents the anticipated course. The luminal outline of the trachea is smooth.

6 Months

The bronchial tree presents with thin walls and tapers uniformly towards the periphery as expected. The lung parenchyma presents the expected architecture and opacity; the intrapulmonary vascular branching is seen up to the third order lung vessels.

INTERPRETED BY

Sebastian Schaub,
 DVM Dr. med. vet.
 DipECVDI

The diaphragm is well delineated with even surface and the expected mild cranial bulging of the diaphragmatic cupola.

RADIOGRAPHIC DIAGNOSIS
HOSPITAL NAME

- Normal thorax

SVS Imaging

INTERPRETATION OF THE FINDINGS & FURTHER RECOMMENDATIONS
REFERRING VET

Dr. Sobon

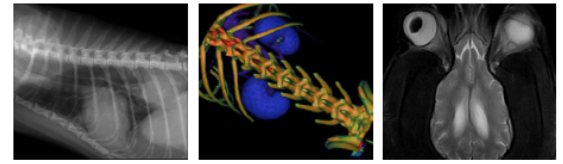
The radiographic study is negative for radiographic changes of the cardiovascular system. A cardiac echo would be ideal for further assessment of the cardiac murmur and to rule out congenital abnormalities.

INVOICE

33547

DATE

12/17/21



PATIENT

Boone Retburg

SPECIES

Canine

BREED

Cavalier King Charles

SEX

Male

AGE

6 Months

INTERPRETED BY

Sebastian Schaub,
DVM Dr. med. vet.
DipECVDI

HOSPITAL NAME

SVS Imaging

REFERRING VET

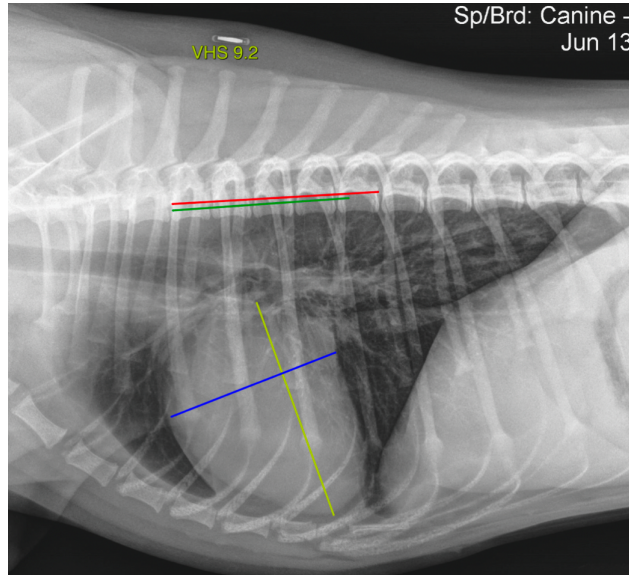
Dr. Sobon

INVOICE

33547

DATE

12/17/21



The information and recommendations provided are based on the images presented by the referring veterinarian. No evaluation can be communicated regarding pathology that was not visible in the image/video clips provided.

Thank you for this referral. If the clinical or image interpretation does not parallel your findings or if I can be of any further assistance please contact me.

Sebastian Schaub, Sebastian Schaub, DVM, Dr. med. vet. DipECVDI
sebast.schaub@gmail.com