

**PATIENT**

Pepper Bulmer

PRESENTING CLINICAL SIGNS

Gastroscopy earlier this year to remove stomach FB. Hard swallowing ever since. 4 cm firm mass behind trachea. U/S suspects FB. FNA unsuccessful. Hard swallowing, regurgitating. On sulcrate and omeprazole.

SPECIES

Canine

COMPUTED TOMOGRAPHY OF THE NECK

A high resolution pre- and post-contrast CT study of the neck is provided for review.

BREED

Spaniel X

COMPUTED TOMOGRAPHIC FINDINGS

Both temporomandibular joints present congruent joint spaces with even subchondral bone surfaces and are considered within normal limits.

SEX

FS

Both tympanic bullae are aerated, the mucosal lining is not seen, the bony wall is smooth and thin. The external ear canals are within normal limits.

The brain presents no deviation from normal anatomy and symmetry. The brain parenchyma is homogeneous and within normal limits for attenuation and distribution of contrast enhancement. The ventricular system is non-dilated and symmetric.

AGE

5 Years

The tonsils appear normal.

INTERPRETED BY

Sebastian Schaub, DVM
Dr. med. vet. DipECVDI

The left medial retropharyngeal lymph node is moderately enlarged, rounded, uniform soft tissue attenuating and heterogeneous contrast enhancing. The fat surrounding the left medial retropharyngeal lymph node presents moderate fat-stranding. The musculature at the same level shows mild increased contrast enhancement pattern.

The thyroid glands are within normal limits for size, shape and organ architecture.

HOSPITAL NAME

Bridgwater
Veterinary Hospital
and Wellness Centre

COMPUTED TOMOGRAPHIC DIAGNOSIS

- Lymphadenopathy right medial retropharyngeal lymph node with surrounding steatitis & myositis

REFERRING VET

Dr. T. Guinn

INTERPRETATION OF THE FINDINGS & FURTHER RECOMMENDATIONS

Potentials for the lymphadenopathy of the left medial retropharyngeal lymph node include (granulomatous) lymphadenitis or neoplastic transformation. No abscess or foreign body is appreciated in the current CT study. Recommend repeating FNA sampling or complementing workup by biopsy including sampling for microbial culture.

INVOICE

49092

Although the tonsil appear normal, palpating the tonsils would be beneficial to rule out neoplastic transformation completely.

DATE

12-16-21



PATIENT

Pepper Bulmer

SPECIES

Canine

BREED

Spaniel X

SEX

FS

AGE

5 Years

INTERPRETED BY

Sebastian Schaub, DVM
Dr. med. vet. DipECVDI

HOSPITAL NAME

Bridgwater
Veterinary Hospital
and Wellness Centre

REFERRING VET

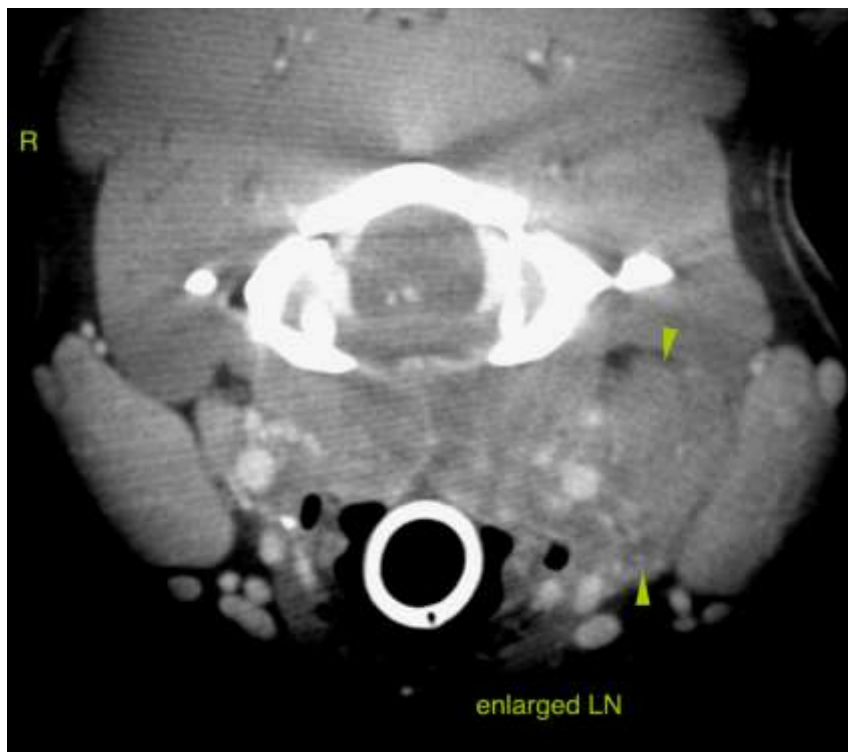
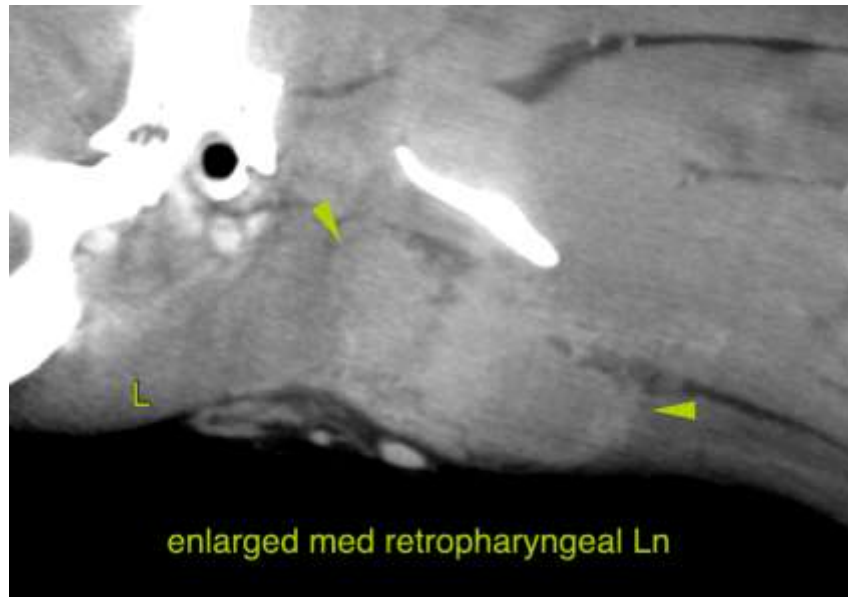
Dr. T. Guinn

INVOICE

49092

DATE

12-16-21





PATIENT

Pepper Bulmer

The information and recommendations provided are based on the images presented by the referring veterinarian. No evaluation can be communicated regarding pathology that was not visible in the image/video clips provided.

Thank you for this referral. If the clinical or image interpretation does not parallel your findings or if I can be of any further assistance please contact me.

SPECIES

Canine

Sebastian Schaub, Sebastian Schaub, DVM, Dr. med. vet. DipECVDI
sebast.schaub@gmail.com

BREED

Spaniel X

SEX

FS

AGE

5 Years

INTERPRETED BY

Sebastian Schaub, DVM
Dr. med. vet. DipECVDI

HOSPITAL NAME

Bridgwater
Veterinary Hospital
and Wellness Centre

REFERRING VET

Dr. T. Guinn

INVOICE

49092

DATE

12-16-21