

**PATIENT**

Chewy Dahlgren

**PRESENTING CLINICAL SIGNS**

Retrolbulbar abscess OD of 3 weeks duration, additional abscesses on head

**SPECIES**

Rabbit

**COMPUTED TOMOGRAPHY OF THE SKULL**

A high resolution pre- and post-contrast CT study of the skull is provided for review.

**BREED**

Netherland Dwarf

Malocclusion of the incisor with splaying of the upper incisors.

**SEX**

Male

**AGE**

2 Years

The premolar and molar teeth in the left jaw quadrants present within normal limits.

The right maxillary premolar and molar teeth present mild to moderate retrograde elongation of the tooth roots. Triadan 410 and 411 present a moderate retrograde growth. Triadan 410 presents a marked bullous widening of the alveolar bone, perforating the lateral cortex. Originating from the widened alveolar crest of triadan 410, a large soft cavitory soft tissue swelling is extending laterally and extending dorsally – medial to the zygomatic arch – into the ventral aspect of the right orbit. Post contrast administration the swelling presents a peripheral contrast enhancing capsule and fluid attenuating center. The right ocular bulb is displaced dorsally by the mass effect. In the rostral aspect the swelling is extending in the subcutaneous tissue at the right aspect of the nose.

**INTERPRETED BY**Sebastian Schaub, DVM  
Dr. med. vet. DipECVDI**COMPUTED TOMOGRAPHIC DIAGNOSIS**

- Large dental abscess originating from triadan 410 with dorsal extend into the right orbit and secondary exophthalmos
- Moderate retrograde growth of maxillary premolar and molar teeth

**HOSPITAL NAME**Parrish Creek  
Veterinary Clinic**INTERPRETATION OF THE FINDINGS & FURTHER RECOMMENDATIONS**

The findings are consistent with dental abscess originating from triadan 410 with extend up into the right orbit. Extraction of triadan 410 and possibly 411 is warranted in combination with drainage and resection of major parts of the abscess capsule – as much as possible.

**REFERRING VET**

Nick Kirk, DVM

**INVOICE**

49106

**DATE**

12-16-21



**PATIENT**

Chewy Dahlgren

**SPECIES**

Rabbit

**BREED**

Netherland Dwarf

**SEX**

Male

**AGE**

2 Years

**INTERPRETED BY**

Sebastian Schaub, DVM  
Dr. med. vet. DipECVDI

**HOSPITAL NAME**

Parrish Creek  
Veterinary Clinic

**REFERRING VET**

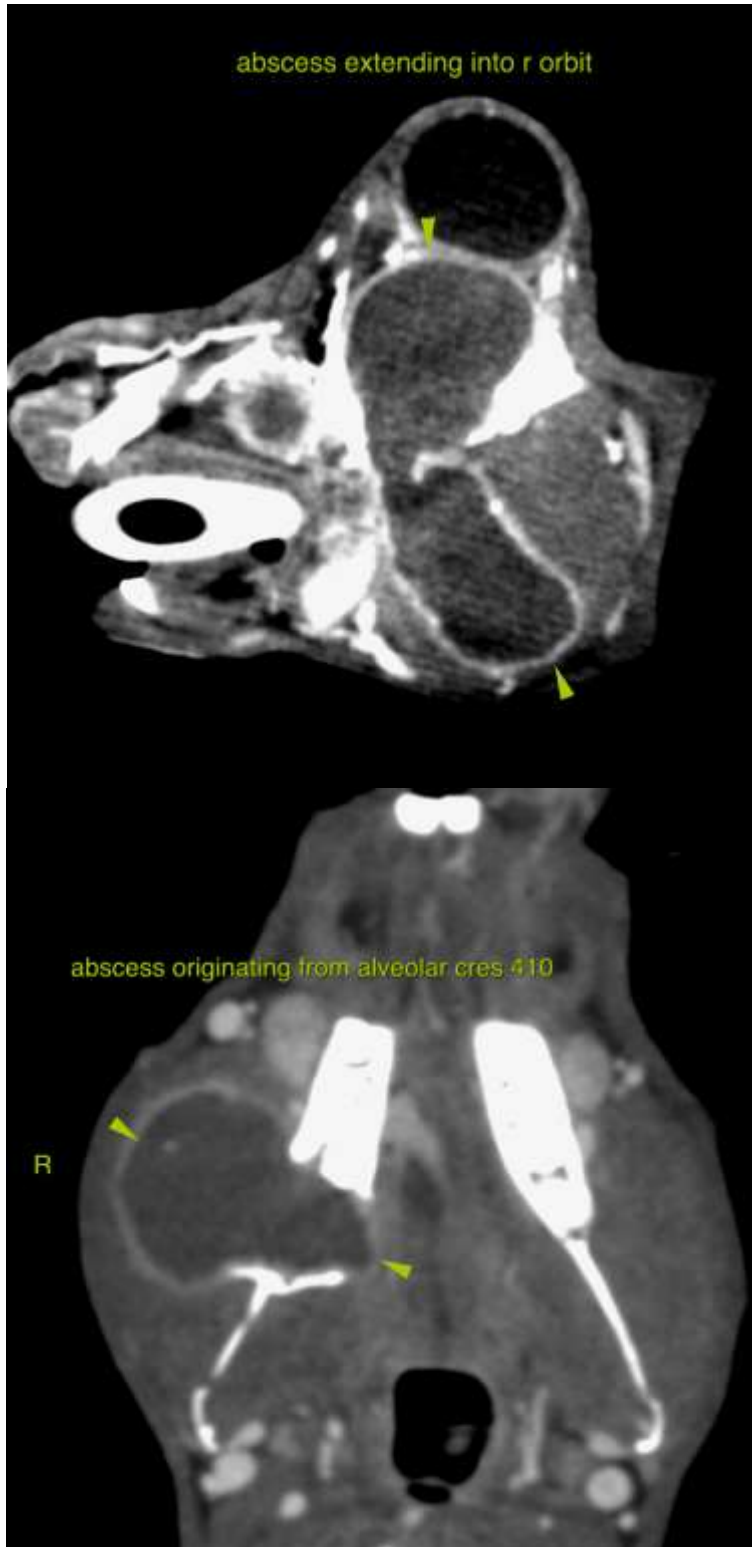
Nick Kirk, DVM

**INVOICE**

49106

**DATE**

12-16-21





**PATIENT**

Chewy Dahlgren

**SPECIES**

Rabbit

**BREED**

Netherland Dwarf

**SEX**

Male

**AGE**

2 Years

**INTERPRETED BY**

Sebastian Schaub, DVM  
Dr. med. vet. DipECVDI

**HOSPITAL NAME**

Parrish Creek  
Veterinary Clinic

**REFERRING VET**

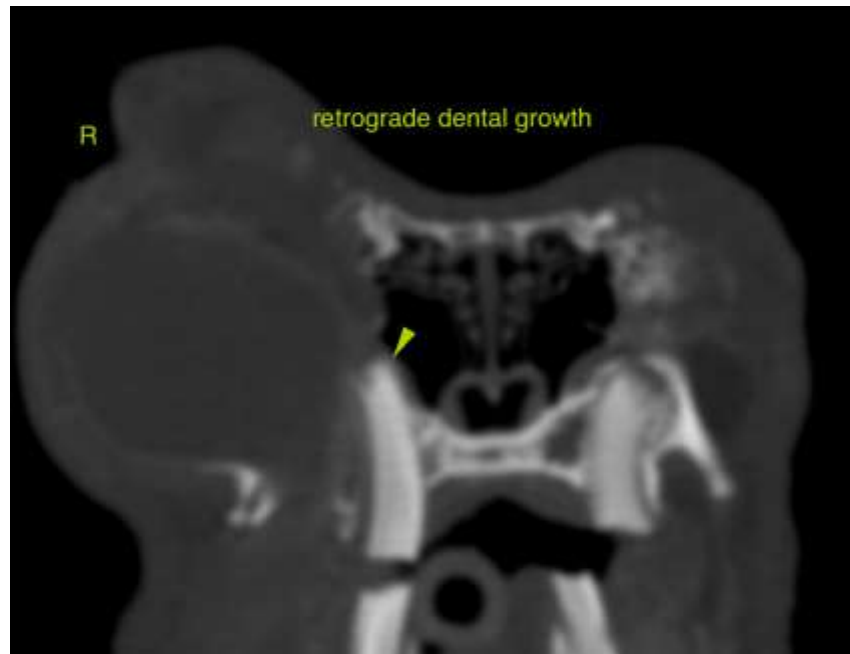Nick Kirk, DVM

**INVOICE**

49106

**DATE**

12-16-21



The information and recommendations provided are based on the images presented by the referring veterinarian. No evaluation can be communicated regarding pathology that was not visible in the image/video clips provided.

Thank you for this referral. If the clinical or image interpretation does not parallel your findings or if I can be of any further assistance please contact me.

**Sebastian Schaub**, Sebastian Schaub, DVM, Dr. med. vet. DipECVDI  
sebast.schaub@gmail.com