



PATIENT

Penelope Panatalone

PRESENTING CLINICAL SIGNS

Last 3 days owner has noticed possible seizures. She goes to vomit, then ends up on her side. Abnormal PE/Chem/CBC/UA Results: Basophils increased, SDMA CREA BUN and PHOS and ALKP are all increased

SPECIES

Canine

RADIOGRAPHIC STUDY OF THE THORAX

Radiographs of the thorax in three imaging planes are provided for review.

BREED

Blue Heeler

RADIOGRAPHIC FINDINGS

The surrounding bony structures are within normal limits.

The extrathoracic soft tissues present homogeneous without abnormalities.

SEX

FS

The heart is of normal size and shape, there is no evidence of cardiac chamber or vascular enlargement. A roundish soft tissue opacity is seen level with the aortic arch in the right lateral projection. The pulmonary vasculature is within normal limits.

AGE

12 Years

The trachea is normal in diameter and presents the anticipated course. The luminal outline of the trachea is smooth.

The bronchial tree presents with thin walls and tapers uniformly towards the periphery as expected.

INTERPRETED BY

Sebastian Schaub, DVM
Dr. med. vet. DipECVDI

The lung parenchyma presents the expected architecture and opacity; the intrapulmonary vascular branching is seen up to the third order lung vessels.

The diaphragm is well delineated with even surface and the expected mild cranial bulging of the diaphragmatic cupola.

HOSPITAL NAME

Cranberry Hill Animal
Hospital

RADIOGRAPHIC DIAGNOSIS

- Suspect normal thorax

REFERRING VET

Dana Robertson-
Piepers

INTERPRETATION OF THE FINDINGS & FURTHER RECOMMENDATIONS

The roundish soft tissue opacity level with the aortic arch in the right lateral projection is considered as the aortic arch and the odds for a pulmonary lesion are low. Unfortunately, the most cranial aspect of the thorax is cropped in the VD projection to completely rule out pulmonary mass. If there is suspicion for thoracic lesion, recommend repeating the VD and right lateral projection of the thorax.

INVOICE

49070

DATE

12-15-21



PATIENT

Penelope Panatalone

SPECIES

Canine

BREED

Blue Heeler

SEX

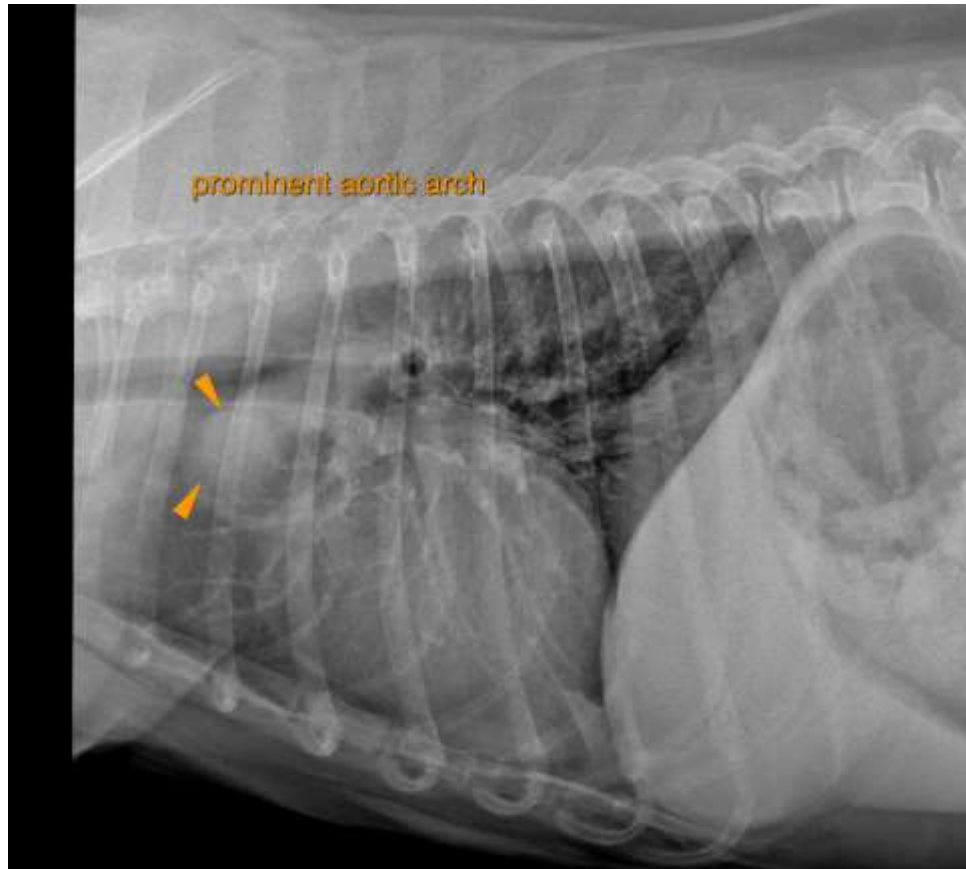
FS

AGE

12 Years

INTERPRETED BY

Sebastian Schaub, DVM
Dr. med. vet. DipECVDI



HOSPITAL NAME

Cranberry Hill Animal
Hospital

REFERRING VET

Dana Robertson-
Piepers

INVOICE

49070

DATE

12-15-21

The information and recommendations provided are based on the images presented by the referring veterinarian. No evaluation can be communicated regarding pathology that was not visible in the image/video clips provided.

Thank you for this referral. If the clinical or image interpretation does not parallel your findings or if I can be of any further assistance please contact me.

Sebastian Schaub, Sebastian Schaub, DVM, Dr. med. vet. DipECVDI
sebast.schaub@gmail.com