



PATIENT PRESENTING CLINICAL SIGNS

Mac Burchell History: Mac is slowing down very fast in last 7 days and is not eating very well and Owner noticed he is hardly getting up after sitting. blood work showed elevation in ALT (337), all other bloodwork was within normal limits . Examining the Musculoskeletal there is no abnormality.

SPECIES Abnormal PE/Chem/CBC/UA Results:

Canine **RADIOGRAPHIC STUDY OF THE ABDOMEN AND LUMBAR SPINE**

BREED The surrounding bony structures are within normal limits. No abnormalities of the lumbar spine are appreciated. Both coxofemoral joints present very mild osteophyte formation level with the junction between the femoral head and neck.

Labrador Retriever

No abnormalities of the extraabdominal soft tissues are noted. The abdominal wall is smooth and thin.

SEX The serosal detail is maintained throughout the peritoneal and retroperitoneal space.

Neutered Male

The liver is appropriate in position, size and presents uniform opacity.

AGE The splenic head is in the anticipated position and within normal limits for size and opacity. The caudal extremity of the spleen presents a rounded cranial margin in the lateral projection.

9 Years

The left kidney presents a convex soft tissue bulge at the lateral aspect. The urinary bladder is in its anticipated position. No radiopaque calculi are noted throughout the upper and lower urinary tract. The stomach is in its anticipated position and presents normal content.

INTERPRETED BY

Sebastian Schaub,
DVM Dr. med. vet.
DipECVDI

The small intestinal loops are of even diameter and non-dilated, a small amount of gas is seen within the small intestinal loops and considered within normal limits.

The colon is seen in the expected position and presents with appropriate content.

HOSPITAL NAME

Truscott AH

RADIOGRAPHIC DIAGNOSIS

- Left renal nodular lesion
- Suspect splenic nodule
- Normal lumbar spine

REFERRING VET

Dr. Medhat Meawad

INTERPRETATION OF THE FINDINGS & FURTHER RECOMMENDATIONS

INVOICE

13069

The renal nodule protruding beyond the surface of the left kidney can present renal cyst, neoplasia, granuloma or less likely abscess.

The rounding of the cranial margin of the caudal extremity of the spleen is very concerning for splenic nodule, such as nodular hyperplasia, hematoma or neoplasia.

DATE

12/15/21



PATIENT

Complementing workup by a complete abdominal ultrasound examination is ideal as advanced imaging modality and next diagnostic step.

Mac Burchell

No radiographic abnormalities of the lumbar spine are appreciated. If there is clinical suspicion for compressive myelopathy, a CT or MRI study can be considered.

SPECIES

Canine

BREED

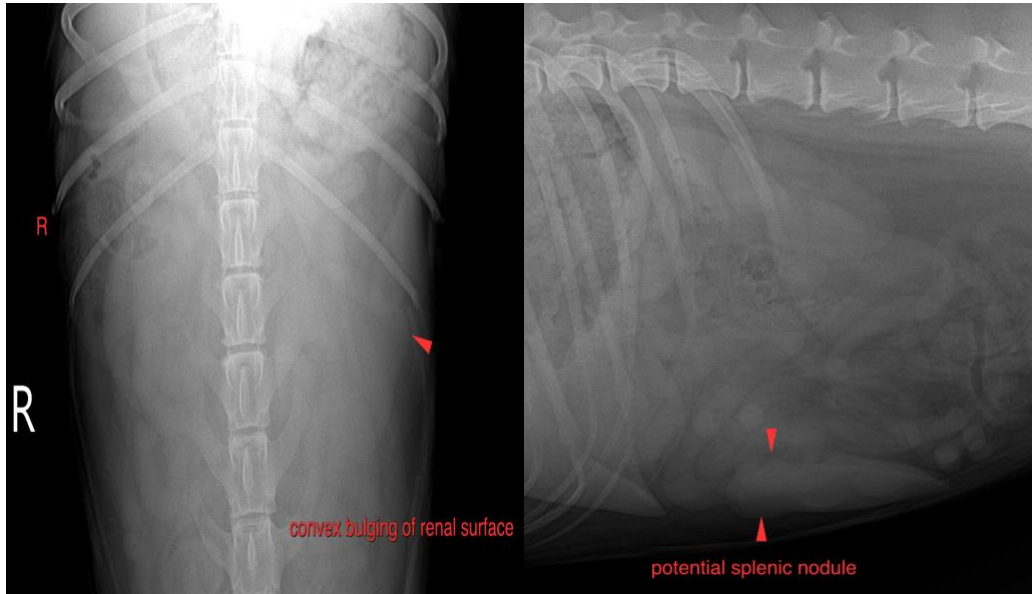
Labrador Retriever

SEX

Neutered Male

AGE

9 Years



INTERPRETED BY

Sebastian Schaub,
DVM Dr. med. vet.
DipECVDI

The information and recommendations provided are based on the images presented by the referring veterinarian. No evaluation can be communicated regarding pathology that was not visible in the image/video clips provided.

Thank you for this referral. If the clinical or image interpretation does not parallel your findings or if I can be of any further assistance please contact me.

HOSPITAL NAME

Truscott AH

Sebastian Schaub, Sebastian Schaub, DVM, Dr. med. vet. DipECVDI
sebast.schaub@gmail.com

REFERRING VET

Dr. Medhat Meawad

INVOICE

13069

DATE

12/15/21