

**PATIENT**

Brodie Brown

PRESENTING CLINICAL SIGNS

Consistent intermittent lameness on left rear leg for months to years.
Abnormal PE/Chem/CBC/UA Results: Left stifle: Very wobbly grade 3/4 MPL, also has slight drawer motion and mild crepitus. Right stifle WNL

SPECIES

Canine

RADIOGRAPHIC STUDY OF THE STIFLE JOINTS

Radiographs of both stifle joints in two orthogonal imaging planes are provided for review.

BREED

Chihuahua

RADIOGRAPHIC FINDINGS

The periarticular bones of both stifle joints present mild osteophyte new bone formation. The right tibial plateau is caudally elongated by new bone formation. Bilaterally an intracapsular mild to moderate soft tissue swelling of the stifle joints is appreciated. The tibia bilaterally is mildly subluxated cranially. The patella bilaterally is in situ

SEX

MN

RADIOGRAPHIC DIAGNOSIS

- Mild degenerative osteoarthritis stifle joints bilaterally
- Mild articular swelling stifle joints bilaterally
- Mild cranial subluxation of the tibia bilaterally
- Caudal elongation right tibial plateau

AGE

9 Years

INTERPRETATION OF THE FINDINGS & FURTHER RECOMMENDATIONS

The radiographic study is suggestive for bilateral failure of the cranial cruciate ligament ± meniscal pathology – right stifle joint presents signs for chronic instability with caudal elongation of the tibial plateau – secondary degenerative osteoarthritis and joint effusion of the stifle joints. As no instability of the right stifle joint was appreciated clinically, the stifle joint has likely been stabilized by the joint capsule.

INTERPRETED BY

Sebastian Schaub, DVM
Dr. med. vet. DipECVDI

HOSPITAL NAME

Northshore
Veterinary Hospital

REFERRING VET

Kristin Williams

INVOICE

55622

DATE

12-14-22



PATIENT

Brodie Brown

SPECIES

Canine

BREED

Chihuahua

SEX

MN

AGE

9 Years

INTERPRETED BY

Sebastian Schaub, DVM
Dr. med. vet. DipECVDI

HOSPITAL NAME

Northshore
Veterinary Hospital

REFERRING VET

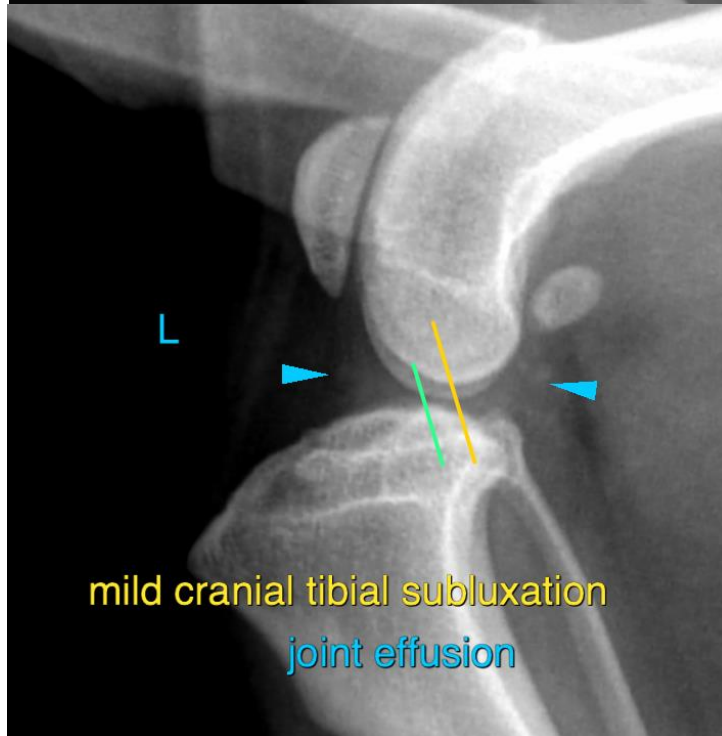
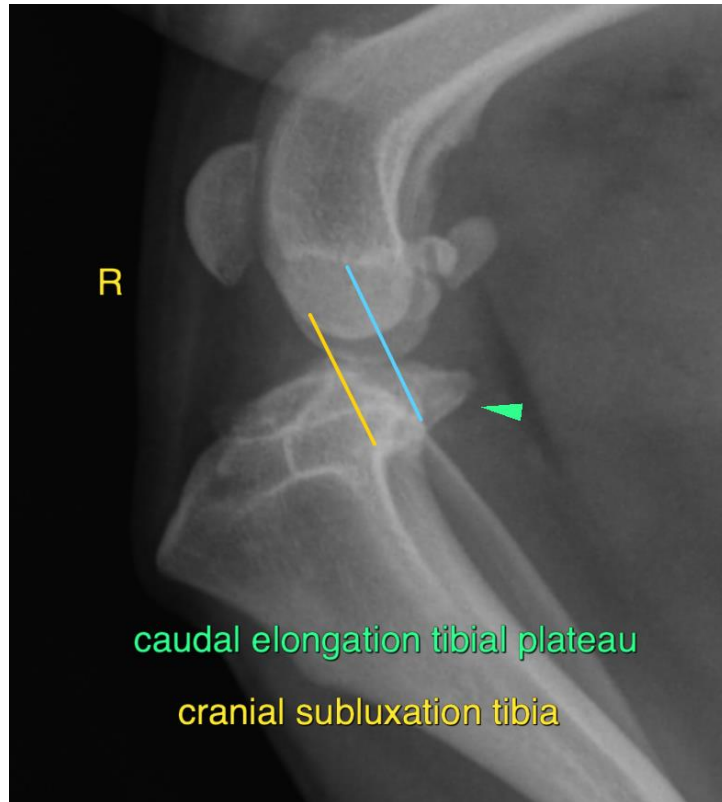
Kristin Williams

INVOICE

55622

DATE

12-14-22





PATIENT

Brodie Brown

SPECIES

Canine

The information and recommendations provided are based on the images presented by the referring veterinarian/sonographer. No evaluation can be communicated regarding pathology that was not visible in the image/video clips provided.

BREED

Chihuahua

Thank you for this referral. If the clinical or image interpretation does not parallel your findings or if I can be of any further assistance please contact me.

SEX

MN

Sebastian Schaub, Sebastian Schaub, DVM, Dr. med. vet. DipECVDI
sebast.schaub@gmail.com

AGE

9 Years

INTERPRETED BY

Sebastian Schaub, DVM
Dr. med. vet. DipECVDI

HOSPITAL NAME

Northshore
Veterinary Hospital

REFERRING VET

Kristin Williams

INVOICE

55622

DATE

12-14-22