

**PATIENT**

Ruth Farrar

PRESENTING CLINICAL SIGNS

Presented for limping on hind legs. O reports P no longer wants to jump or run like she used to and is showing a decrease in activity. Will intermittently limp on both leg or hold a leg up for a few steps, more so on the right, but also the left hind, while walking or at a trot.

SPECIES

Canine

Abnormal PE/Chem/CBC/UA Results: Grade IV/IV MPL bilateral on stifles, BCS 7/9

RADIOGRAPHIC STUDY OF THE STIFLE JOINTS

Radiographs of the stifle joints in two imaging planes are provided for review.

BREED

Yorkshire Terrier

RADIOGRAPHIC FINDINGS

In the mediolateral projection of the left stifle joint, the patella is superimposed on the femoral condyles.

SEX

FS

In the craniocaudal projection of the stifle joints, the patella of both stifle joints is seen medial to the medial femoral condyle respectively. Both stifle joints present evidence of mild intracapsular swelling.

AGE

1.5 Years

RADIOGRAPHIC DIAGNOSIS

- Bilateral medial patellar luxation
- Bilateral mild articular swelling of the stifle joints

INTERPRETED BY

Sebastian Schaub, DVM
Dr. med. vet. DipECVDI

INTERPRETATION OF THE FINDINGS & FURTHER RECOMMENDATIONS

The radiographic study is fitting the history of bilateral medial patellar luxation with secondary mild joint effusion. No additional abnormalities are appreciated and there are no signs for angular limb deformity. Consider surgical intervention for correction of the medial patellar luxation.

HOSPITAL NAME

Boca Park Animal
Hospital

REFERRING VET

Ashman

INVOICE

49026

DATE

12-14-21



PATIENT

Ruth Farrar

SPECIES

Canine

BREED

Yorkshire Terrier

SEX

FS

AGE

1.5 Years

INTERPRETED BY

Sebastian Schaub, DVM
Dr. med. vet. DipECVDI

HOSPITAL NAME

Boca Park Animal
Hospital

REFERRING VET

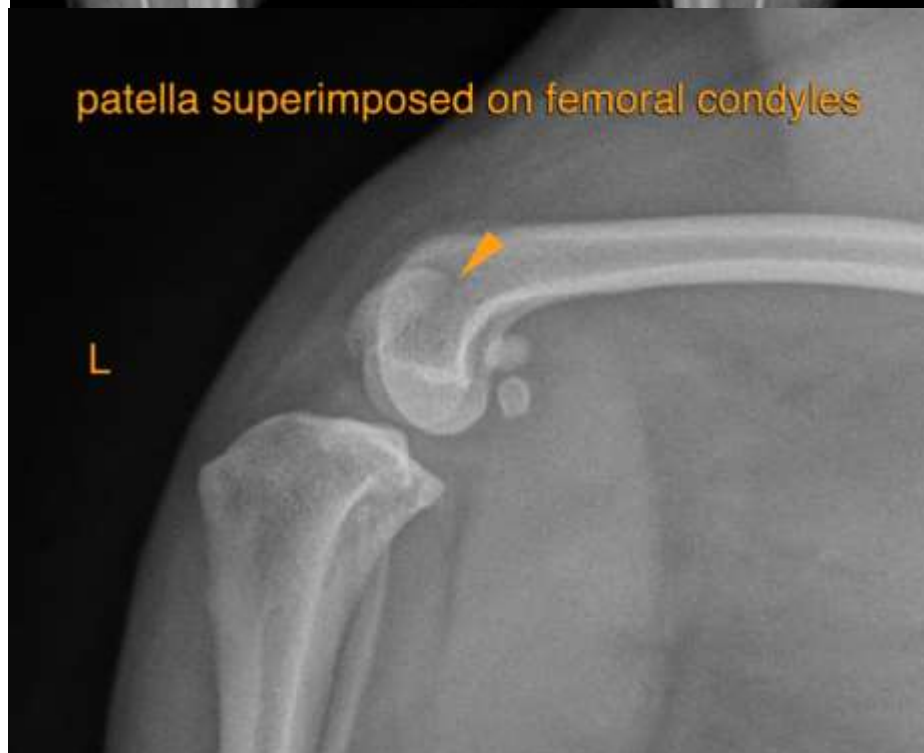
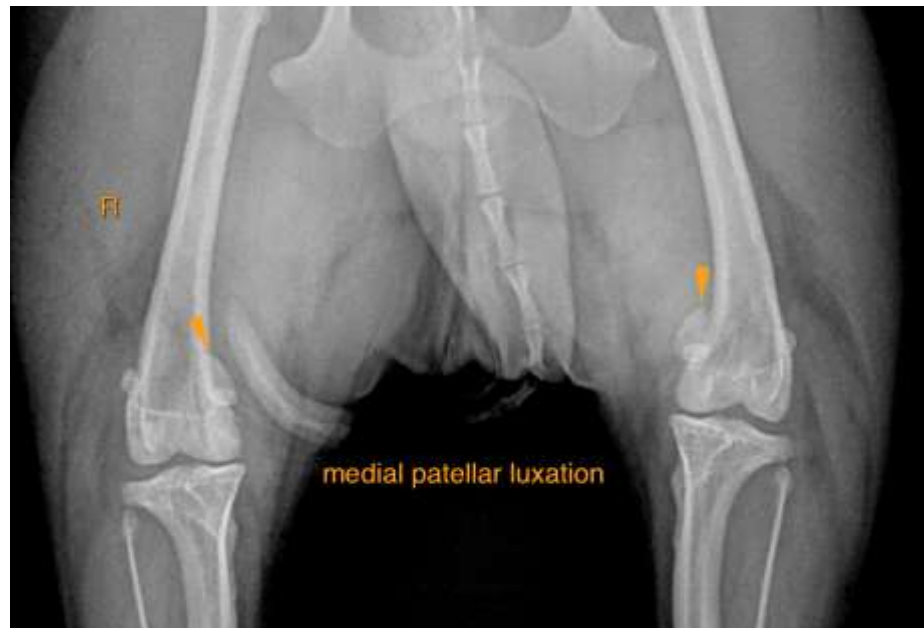Ashman

INVOICE

49026

DATE

12-14-21





PATIENT

Ruth Farrar

The information and recommendations provided are based on the images presented by the referring veterinarian. No evaluation can be communicated regarding pathology that was not visible in the image/video clips provided.

SPECIES

Canine

Thank you for this referral. If the clinical or image interpretation does not parallel your findings or if I can be of any further assistance please contact me.

Sebastian Schaub, Sebastian Schaub, DVM, Dr. med. vet. DipECVDI
sebast.schaub@gmail.com

BREED

Yorkshire Terrier

SEX

FS

AGE

1.5 Years

INTERPRETED BY

Sebastian Schaub, DVM
Dr. med. vet. DipECVDI

HOSPITAL NAME

Boca Park Animal
Hospital

REFERRING VET

Ashman

INVOICE

49026

DATE

12-14-21