



**PATIENT PRESENTING CLINICAL SIGNS**

Kozy Guy  
vomiting and diarrhea, not eating much  
Abnormal PE/Chem/CBC/UA Results: PE NSF

**SPECIES RADIOGRAPHIC STUDY OF THE ABDOMEN**

Canine  
Radiographs of the abdomen in three imaging planes are provided for review.

**RADIOGRAPHIC FINDINGS**

The surrounding bony structures are within normal limits.

No abnormalities of the extraabdominal soft tissues are noted. The abdominal wall is smooth and thin.

**SEX**

The serosal detail is maintained throughout the peritoneal and retroperitoneal space.

**MN**

The liver is appropriate in position, size and presents uniform opacity.

**AGE**

The splenic head is in the anticipated position and within normal limits for size and opacity. The splenic body and tail are considered normal for position, size, shape and opacity.

2.5 Years

Both kidneys are seen and present with normal size, shape, delineation and opacity. The urinary bladder is in its anticipated position. No radiopaque calculi are noted throughout the upper and lower urinary tract.

**INTERPRETED BY**

Sebastian Schaub, DVM  
Dr. med. vet. DipECVDI

The stomach is in its anticipated position and is empty.

The small intestinal loops are of even diameter and non-dilated, a small amount of gas is seen within the small intestinal loops and considered within normal limits.

**HOSPITAL NAME**

Boca Park Animal  
Hospital

The colon is seen in the expected position and contains a mild amount of unformed fecal material.

**RADIOGRAPHIC DIAGNOSIS**

**REFERRING VET**

Morgan Spaulding

- Empty stomach
- Unformed fecal material in colon

**INTERPRETATION OF THE FINDINGS & FURTHER RECOMMENDATIONS**

**INVOICE**

49046

The presumptive diagnosis for the radiographic findings is gastroenteritis. There is no evidence of radiopaque foreign material or signs for gastrointestinal mechanical obstruction. If clinical signs are refractory to therapy, recommend follow up radiographs or a complete abdominal ultrasound examination.

**DATE**

12-14-21



**PATIENT**

Kozy Guy

**SPECIES**

Canine

**BREED**

Golden Retriever

**SEX**

MN

**AGE**

2.5 Years

**INTERPRETED BY**

Sebastian Schaub, DVM  
Dr. med. vet. DipECVDI

**HOSPITAL NAME**

Boca Park Animal  
Hospital

**REFERRING VET**

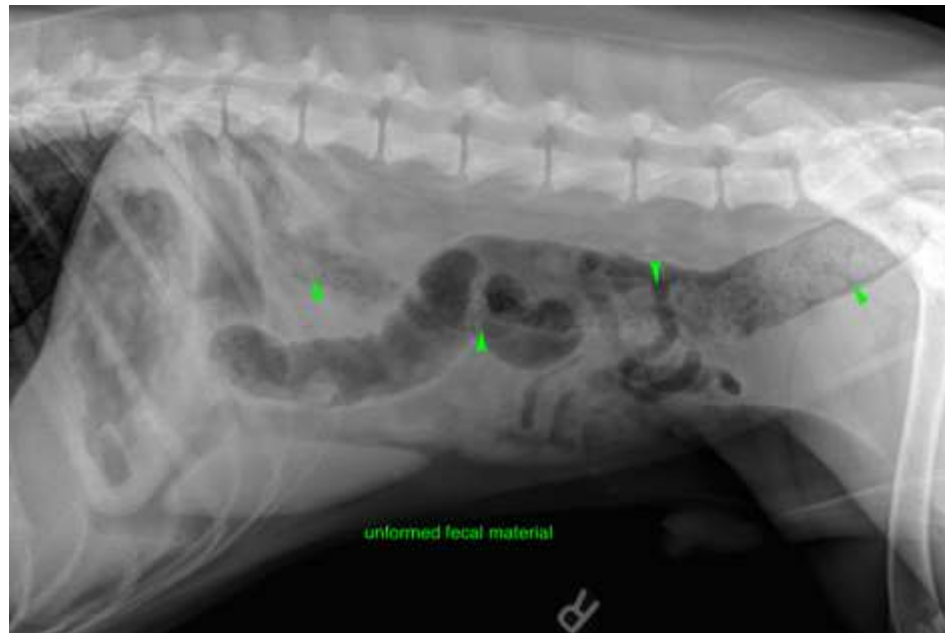
Morgan Spaulding

**INVOICE**

49046

**DATE**

12-14-21



The information and recommendations provided are based on the images presented by the referring veterinarian. No evaluation can be communicated regarding pathology that was not visible in the image/video clips provided.

Thank you for this referral. If the clinical or image interpretation does not parallel your findings or if I can be of any further assistance please contact me.

**Sebastian Schaub**, Sebastian Schaub, DVM, Dr. med. vet. DipECVDI  
sebast.schaub@gmail.com