



PATIENT

Rocco Dawn

PRESENTING CLINICAL SIGNS

Acting lethargic for a day, inappetant since yesterday, vomited right after eating
 Abnormal PE/Chem/CBC/UA Results: dehydration- 5%, drug toxicity test- positive for marijuana, ALT moderately elevated 700 (0-120),

SPECIES

Canine

RADIOGRAPHIC STUDY OF THE ABDOMEN

Radiographs of the abdomen in three imaging planes are provided for review.

BREED

French Bulldog

RADIOGRAPHIC FINDINGS

Both coxofemoral joints present mild osteophyte new bone formation. The acetabular groove bilaterally is shallow, and the center of the femoral heads is lateral to the dorsal acetabular rim.

No abnormalities of the extraabdominal soft tissues are noted. The abdominal wall is smooth and thin.

SEX

Male

The serosal detail is maintained throughout the peritoneal and retroperitoneal space.

AGE

21 Months

The liver is appropriate in position, size and presents uniform opacity.

The splenic head is in the anticipated position and within normal limits for size and opacity. The splenic body and tail are considered normal for position, size, shape and opacity.

Both kidneys are seen and present with normal size, shape, delineation and opacity. The urinary bladder is in its anticipated position. No radiopaque calculi are noted throughout the upper and lower urinary tract.

INTERPRETED BY

Sebastian Schaub, DVM
 Dr. med. vet. DipECVDI

The stomach is in its anticipated position and empty, but a small amount of gas.

The small intestinal loops are of even diameter and non-dilated, a small amount of gas is seen within the small intestinal loops and considered within normal limits.

HOSPITAL NAME

St. Catherine's Animal
 Hospital

The colon is seen in the expected position and is empty.

RADIOGRAPHIC DIAGNOSIS

- Empty gastrointestinal tract

REFERRING VET

Dr. Jui Gokhale

INTERPRETATION OF THE FINDINGS & FURTHER RECOMMENDATIONS

The generalized empty gastrointestinal tract in combination with the presenting clinical signs is suggestive for gastroenteritis. There is no evidence of radiopaque foreign material or signs for gastrointestinal mechanical obstruction. If clinical signs are refractory to therapy, recommend follow up radiographs or a complete abdominal ultrasound examination; in some cases a high ileus may lack classical radiographic signs of mechanical obstruction.

INVOICE

55575

DATE

12-13-22



PATIENT

Rocco Dawn

SPECIES

Canine

BREED

French Bulldog

SEX

Male

AGE

21 Months

INTERPRETED BY

Sebastian Schaub, DVM
Dr. med. vet. DipECVDI

HOSPITAL NAME

St. Catherine's Animal
Hospital

REFERRING VET

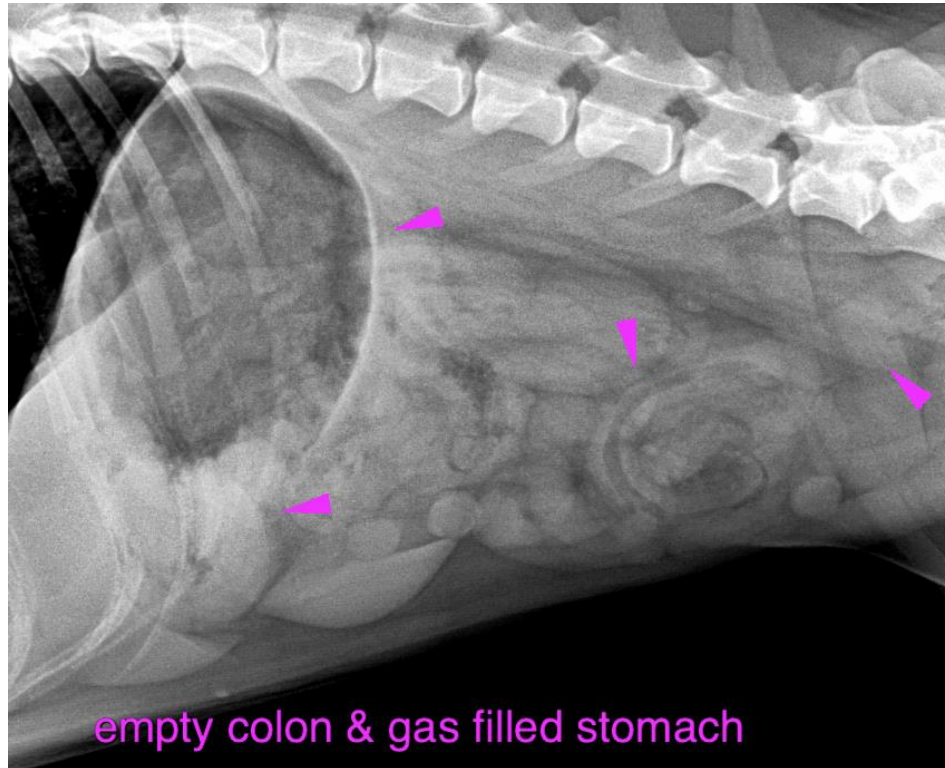
Dr. Jui Gokhale

INVOICE

55575

DATE

12-13-22



The information and recommendations provided are based on the images presented by the referring veterinarian/sonographer. No evaluation can be communicated regarding pathology that was not visible in the image/video clips provided.

Thank you for this referral. If the clinical or image interpretation does not parallel your findings or if I can be of any further assistance please contact me.

Sebastian Schaub, Sebastian Schaub, DVM, Dr. med. vet. DipECVDI
sebast.schaub@gmail.com