



PATIENT

Cassandra Streiling

PRESENTING CLINICAL SIGNS

Presented for the complaint of an eye infection. Examination reveals a very swollen face -- only right side of face is affected. Eyes is shut due to inflammation of surrounding tissues. O advised the cat has had a squinty eye for 2 weeks. Indoor only but does get into occasional fight with the cat housemates.

SPECIES

Feline

Abnormal PE/Chem/CBC/UA Results: none done History of chronic renal failure

RADIOGRAPHIC STUDY OF THE SKULL

BREED

DSH

A full set of radiographs of the skull is provided for review.

RADIOGRAPHIC FINDINGS

All teeth are absent.

SEX

SF

A moderate to marked subcutaneous soft tissue swelling is seen at the right dorsal aspect of the viscerocranium with multiple gas opacities in the dorsal aspect. The right nasal cavity presents a generalized increased soft tissue opacity, most accentuated in the dorsal aspect. In the rostrocaudal projection, the osseous margins of the right maxillary bone appear mildly rough with moth eaten osteolytic lesions.

AGE

16 Years

No additional abnormalities.

INTERPRETED BY

Sebastian Schaub, DVM
Dr. med. vet. DipECVDI

RADIOGRAPHIC DIAGNOSIS

- Soft tissue swelling right dorsolateral aspect of the viscerocranium with potential semiaggressive osteolytic lesions
- Soft tissue opacification right nasal cavity
- Suspect history of full mouth dental extraction

HOSPITAL NAME

Balmy Beach Pet Hospital

INTERPRETATION OF THE FINDINGS & FURTHER RECOMMENDATIONS

The swelling at the right dorsolateral aspect of the viscerocranium is concerning for neoplastic disease with potential invasion/origin from the right nasal cavity – with potential osteolytic lesions – such as squamous cell carcinoma, fibrosarcoma, chondrosarcoma, other. The odds for primary inflammatory origin of the swelling are considered lower. However, FNA sampling/biopsy is warranted for further definition. CT study can be also used as advanced imaging modality.

REFERRING VET

Dr. Yogo

INVOICE

48954

DATE

12-11-21



PATIENT

Cassandra Streiling

SPECIES

Feline

BREED

DSH

SEX

SF

AGE

16 Years

INTERPRETED BY

Sebastian Schaub, DVM
Dr. med. vet. DipECVDI

HOSPITAL NAME

Balmy Beach Pet
Hospital

REFERRING VET

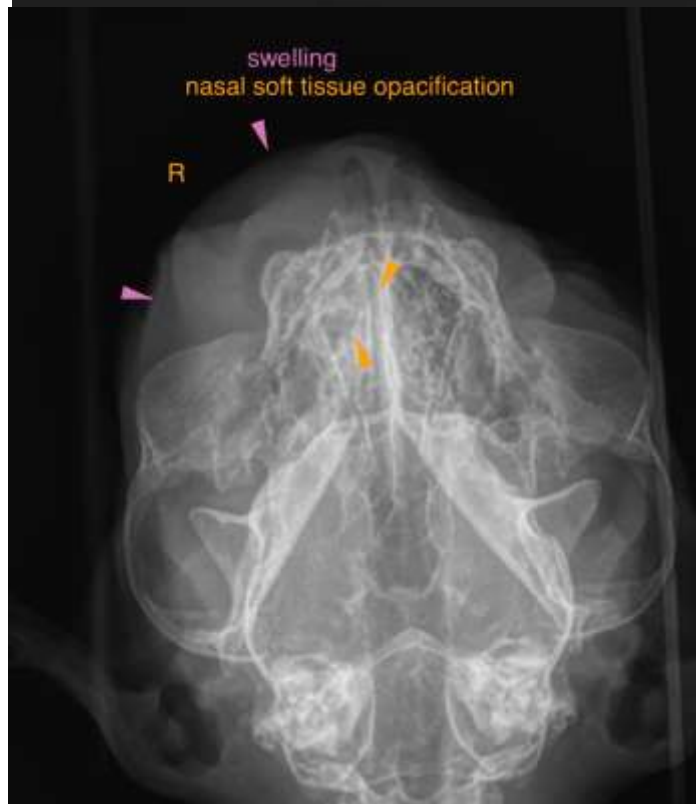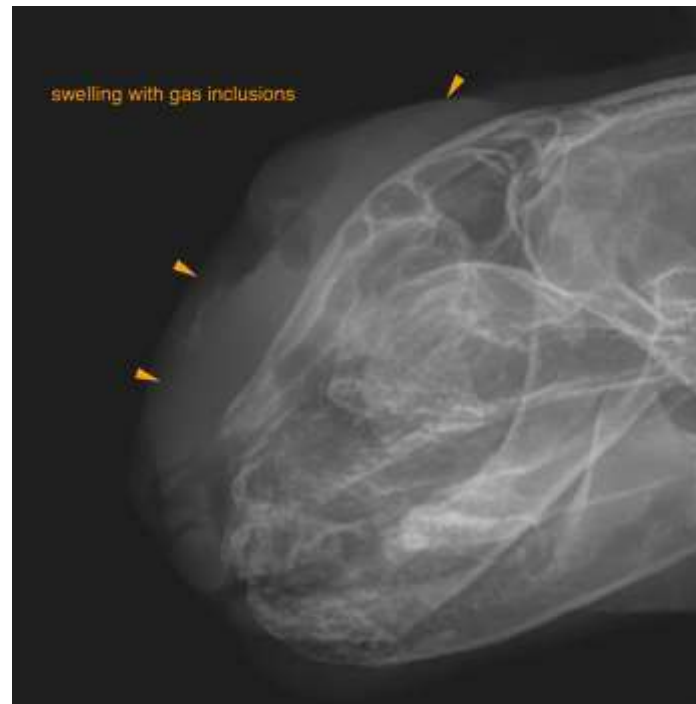
Dr. Yogo

INVOICE

48954

DATE

12-11-21





PATIENT

Cassandra Streiling

SPECIES

Feline

BREED

DSH

SEX

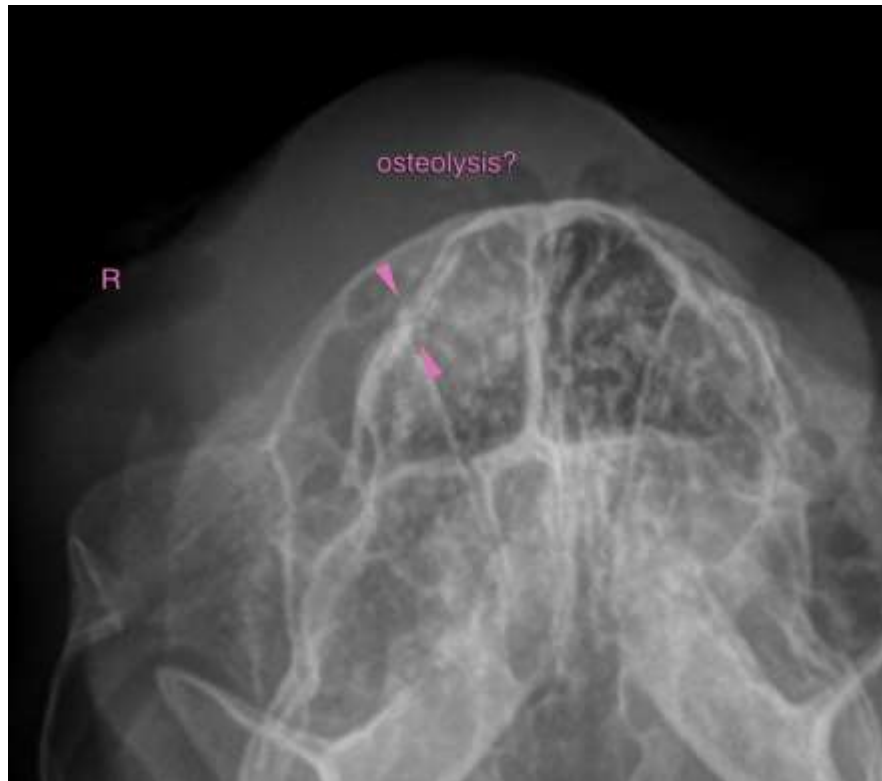SF

AGE

16 Years

INTERPRETED BY

Sebastian Schaub, DVM
Dr. med. vet. DipECVDI



HOSPITAL NAME

Balmy Beach Pet
Hospital

REFERRING VET

Dr. Yogo

INVOICE

48954

DATE

12-11-21

The information and recommendations provided are based on the images presented by the referring veterinarian. No evaluation can be communicated regarding pathology that was not visible in the image/video clips provided.

Thank you for this referral. If the clinical or image interpretation does not parallel your findings or if I can be of any further assistance please contact me.

Sebastian Schaub, Sebastian Schaub, DVM, Dr. med. vet. DipECVDI
sebast.schaub@gmail.com