



## PATIENT

Pumpkin 2 C1981  
Animals in Distress

## SPECIES

Feline

## BREED

Domestic Shorthair

## SEX

Spayed Female

## AGE

16Y, 9M

## WEIGHT

11.14

## INTERPRETED BY

Sebastian Schaub, DVM  
Dr. med. vet.  
DipECVDI

## IMAGING PERFORMED BY

Renee Ziegler Post

## HOSPITAL NAME

For Cats Only  
Veterinary Clinic

## REFERRING VET

Renee Ziegler Post

## INVOICE

72949

## DATE

12-10-25

## PRESENTING CLINICAL SIGNS

I used red arrows to highlight a question, and I thought the bullae looked asymmetric; sounds congested; has persisting leukocytosis, thick mucus above palate.

Abnormal PE/Chem/CBC/UA Results: Cultured normal flora and viral PCR negative, was positive for mycoplasma

## RADIOGRAPHIC STUDY OF THE SKULL

Radiographs of the skull in a laterolaterale and rostrocaudal view are provided for review.

## RADIOGRAPHIC FINDINGS

All teeth are absent.

The nasal cavity presents a subjectively increased radiopacity in the lateral view. The nasopharynx is aerated.

The wall of the tympanic bullae is mildly thickened and smooth. The tympanic bullae are aerated.

The surrounding soft tissue structures of the skull reveals no abnormalities.

## RADIOGRAPHIC DIAGNOSIS

- Suspect soft tissue opacification of the nasal cavity
- Signs of preceding chronic otitis media
- History of full mouth dental extraction

## INTERPRETATION OF THE FINDINGS & FURTHER RECOMMENDATIONS

The supposed increased radiopacity of the nasal cavity can be caused by mucus or nasal soft tissue mass (e.g. neoplasia, granuloma). Either a CT study of the skull or rhinoscopy can be used as advanced diagnostic tool.



## PATIENT

Pumpkin 2 C1981  
Animals in Distress

## SPECIES

Feline

## BREED

Domestic Shorthair

## SEX

Spayed Female

## AGE

16Y, 9M

## WEIGHT

11.14

## INTERPRETED BY

Sebastian Schaub, DVM  
Dr. med. vet.  
DipECVDI

## IMAGING PERFORMED BY

Renee Ziegler Post

## HOSPITAL NAME

For Cats Only  
Veterinary Clinic

## REFERRING VET

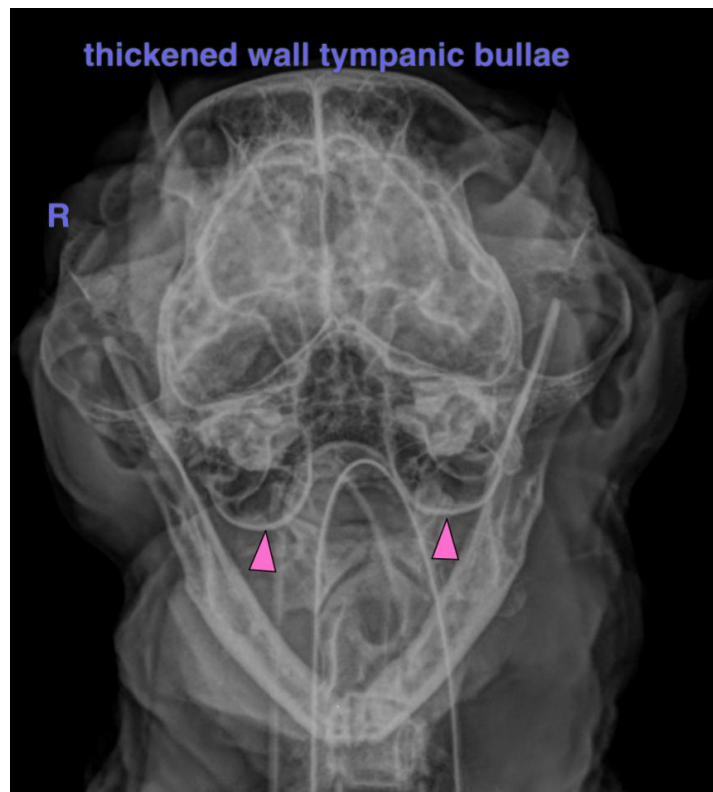
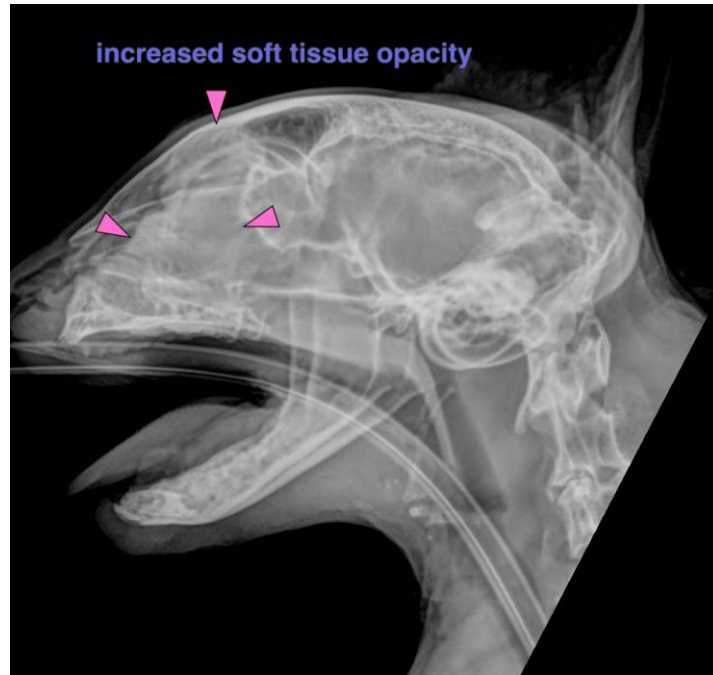
Renee Ziegler Post

## INVOICE

72949

## DATE

12-10-25





## PATIENT

Pumpkin 2 C1981  
Animals in Distress

## SPECIES

Feline

## BREED

Domestic Shorthair

## SEX

Spayed Female

## AGE

16Y, 9M

## WEIGHT

11.14

## INTERPRETED BY

Sebastian Schaub, DVM  
Dr. med. vet.  
DipECVDI

## IMAGING PERFORMED BY

Renee Ziegler Post

## HOSPITAL NAME

For Cats Only  
Veterinary Clinic

## REFERRING VET

Renee Ziegler Post

## INVOICE

72949

## DATE

12-10-25

The information and recommendations provided are based on the images presented by the referring veterinarian/sonographer. No evaluation can be communicated regarding pathology that was not visible in the image/video clips provided.

Thank you for this referral. If the clinical or image interpretation does not parallel your findings or if I can be of any further assistance please contact me.

**Sebastian Schaub**, Sebastian Schaub, DVM, Dr. med. vet. DipECVDI  
[info@sonopath.com](mailto:info@sonopath.com)