



## PATIENT

Peanut Micale

## SPECIES

Canine

## BREED

French Bulldog

## SEX

FS

## AGE

5Y, 9M

## WEIGHT

11.6kg

## INTERPRETED BY

Sebastian Schaub, DVM  
Dr. med. vet.  
DipECVDI

## IMAGING PERFORMED BY

David Rivera/Christina  
Nunez

## HOSPITAL NAME

Animal Surgical Center  
- Oceanside

## REFERRING VET

Dr. Kamran  
Babamohammadi

## INVOICE

72792

## DATE

12-1-25

## PRESENTING CLINICAL SIGNS

History of BOAS surgery (soft palate and nares). Client noticed increased upper respiratory sounds within the past 2 months.

## COMPUTED TOMOGRAPHY OF THE SKULL, NECK AND THORAX

A high resolution pre- and post-contrast CT study of the skull, neck and thorax is provided for review.

## COMPUTED TOMOGRAPHIC FINDINGS

### Skull & Neck

The skull has a brachycephalic conformation with significant crowding and rotation of the maxillary premolar teeth.

The tooth elements 109, 302, 303, 305, 3011, 402, 411 are absent. The tooth elements 107, 110 207, 209, 210 present a moderate widened periodontal space.

The nasal cavity presents the expected aerated spaces between thin & even conchae and turbinates with smooth mucosal lining. The soft palate is thickened, measuring up to 10 mm.

Both temporomandibular joints present congruent joint spaces with even subchondral bone surfaces and are considered within normal limits.

Both tympanic bullae are aerated, the mucosal lining is not seen, the bony wall is smooth and thin. The external ear canals are within normal limits.

The brain presents no deviation from normal anatomy and symmetry. The brain parenchyma is homogeneous and within normal limits for attenuation and distribution of contrast enhancement. The ventricular system is non-dilated and symmetric.

The submandibular and medial retropharyngeal lymph nodes are small and elongated with a normal short-to-long-axis-ratio is < 0.5, the attenuation and contrast enhancement pattern is uniform.

### Thorax

Multiple thoracic vertebra present variable degree of congenital malformation - presenting as hemivertebra. Along the thoracic spine, multifocal spondylosis formation is seen.

The sternal, cranial mediastinal and tracheobronchial lymph nodes are small elongated with a normal short-to-long-axis-ratio is < 0.5, the attenuation and contrast enhancement pattern is uniform and considered within normal limits.

The cardiovascular structures including the pulmonary vasculature are within normal limits.

The bronchial tree presents with regular branching and tapers uniformly towards the periphery as expected, the bronchial walls are thin and smooth. The bronchus-to-artery ratio is within normal limits.

Throughout the lung parenchyma, multiple, well-defined, soft tissue attenuating nodules are seen; measuring up to 6 mm in diameter.

Small incidental gas pockets are seen within the esophageal lumen; there is no evidence of abnormal dilation.

Originating from the right adrenal gland, a uniform soft tissue attenuating and mild irregular contrast enhancing mass is seen; measuring 15 x 14 x 18 mm. Level with the orifice of the right phrenicoabdominal vein in the caudal vena cava, an intraluminal ill-defined filling defects is seen.



## PATIENT

Peanut Micale

## SPECIES

Canine

## BREED

French Bulldog

## SEX

FS

## AGE

5Y, 9M

## WEIGHT

11.6kg

## INTERPRETED BY

Sebastian Schaub, DVM  
Dr. med. vet.  
DipECVDP

## IMAGING PERFORMED BY

David Rivera/Christina  
Nunez

## HOSPITAL NAME

Animal Surgical Center  
- Oceanside

## REFERRING VET

Dr. Kamran  
Babamohammadi

## INVOICE

72792

## DATE

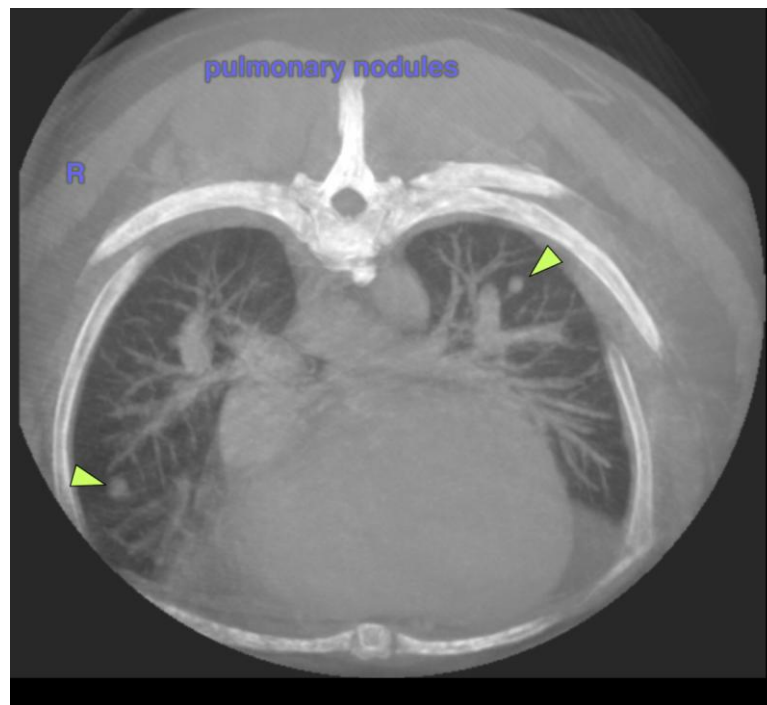
12-1-25

## COMPUTED TOMOGRAPHIC DIAGNOSIS

- Right adrenal soft tissue mass with vascular invasion
- Structured nodular interstitial lung pattern
- Thickened soft palate
- Periodontal disease 107, 110 207, 209, 210
- Multiple absent teeth
- Congenital malformation multiple thoracic vertebra
- Spondylosis deformans

## INTERPRETATION OF THE FINDINGS & FURTHER RECOMMENDATIONS

The main finding is the right adrenal soft tissue mass, invading the caudal vena cava – consistent with primary adrenal neoplasia (e.g. adenocarcinoma, pheochromocytoma). The structured nodular lung pattern is indicative for secondary pulmonary metastatic disease.





## PATIENT

Peanut Micale

## SPECIES

Canine

## BREED

French Bulldog

## SEX

FS

## AGE

5Y, 9M

## WEIGHT

11.6kg

## INTERPRETED BY

Sebastian Schaub, DVM  
Dr. med. vet.  
DipECVDI

## IMAGING PERFORMED BY

David Rivera/Christina  
Nunez

## HOSPITAL NAME

Animal Surgical Center  
- Oceanside

## REFERRING VET

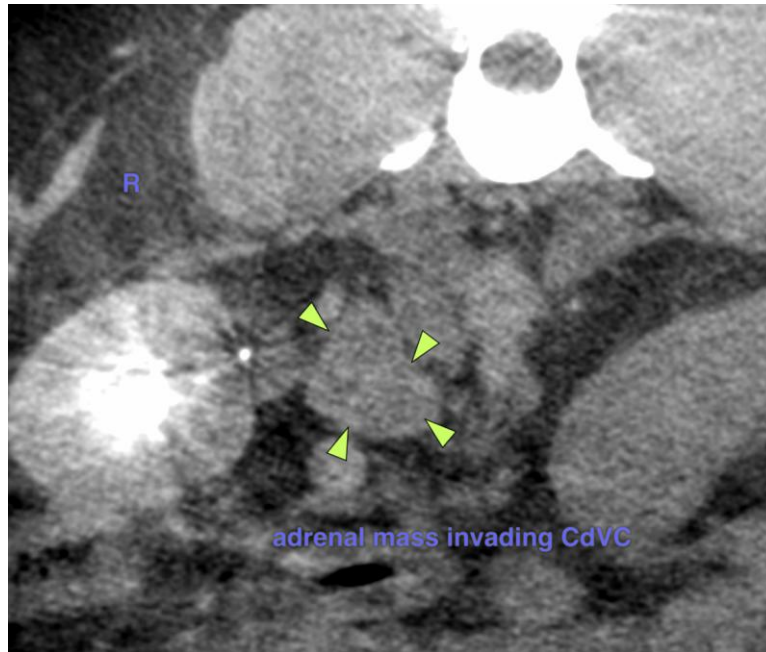
Dr. Kamran  
Babamohammadi

## INVOICE

72792

## DATE

12-1-25



The information and recommendations provided are based on the images presented by the referring veterinarian/sonographer. No evaluation can be communicated regarding pathology that was not visible in the image/video clips provided.

Thank you for this referral. If the clinical or image interpretation does not parallel your findings or if I can be of any further assistance please contact me.

**Sebastian Schaub**, Sebastian Schaub, DVM, Dr. med. vet. DipECVDI  
[info@sonopath.com](mailto:info@sonopath.com)