



PATIENT

Henry Soloniewicz

SPECIES

Canine

BREED

Shih Tzu

SEX

MN

AGE

10

WEIGHT

8.1

INTERPRETED BY

Sebastian Schaub, DVM
Dr. med. vet.
DipECVDI

IMAGING PERFORMED BY

Patricia Sanchez
Sanchez

HOSPITAL NAME

Animal Trust - Bolton

REFERRING VET

Patricia Sanchez
Sanchez

INVOICE

72789

DATE

12-1-25

PRESENTING CLINICAL SIGNS

Severe lameness in RFL, more severe after jumping from the sofa

COMPUTED TOMOGRAPHY OF THE SHOULDER AND ELBOW JOINTS

A high resolution plain CT study of the shoulder and elbow joints is provided for review.

COMPUTED TOMOGRAPHIC FINDINGS

Both shoulder joints present smooth margins of the periarticular bones and the surrounding soft tissue structures are within normal limits.

The periarticular bones of both elbow joints present moderate osteophyte new bone formation. The joint space of the elbow joints is congruent. The surrounding soft tissue structures of the elbow joints present without abnormalities.

The antebrachium bilaterally presents a mild to moderate pro-curvatum conformation.

COMPUTED TOMOGRAPHIC DIAGNOSIS

- Moderate osteoarthritis elbow joint bilaterally
- Pro-curvatum conformation antebrachium bilaterally – no signs of relevant incongruity of the elbow joints
- Normal shoulder joints

INTERPRETATION OF THE FINDINGS & FURTHER RECOMMENDATIONS

The main finding is the degenerative joint disease of both elbow joints. An acute exacerbation of a chronic condition may have contributed to the recent development of clinical signs. If there is strong suspicion for underlying soft tissue injury or pain originating from the neck, consider a plain and post contrast CT of the neck and brachial plexus region.



PATIENT

Henry Soloniewicz

SPECIES

Canine

BREED

Shih Tzu

SEX

MN

AGE

10

WEIGHT

8.1

INTERPRETED BY

Sebastian Schaub, DVM
Dr. med. vet.
DipECVDI

IMAGING PERFORMED BY

Patricia Sanchez
Sanchez

HOSPITAL NAME

Animal Trust - Bolton

REFERRING VET

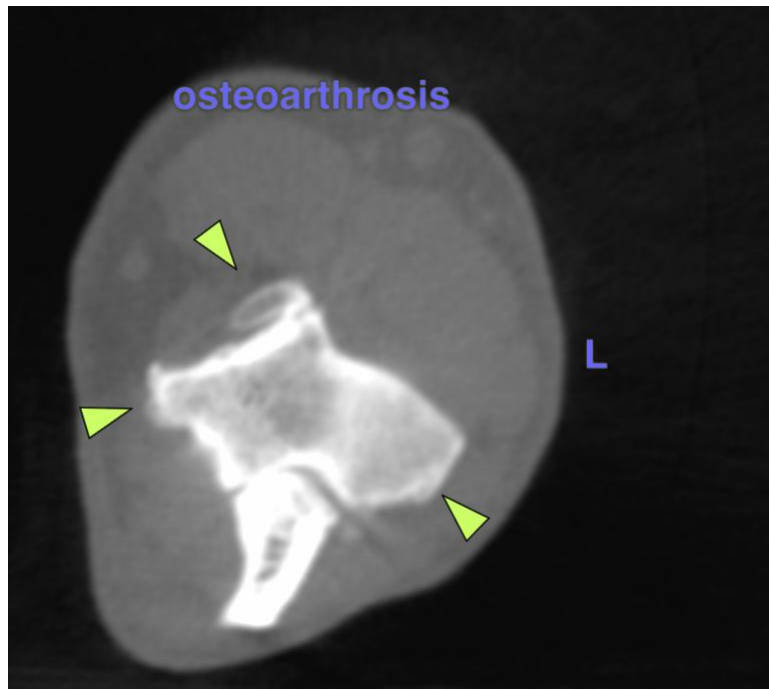
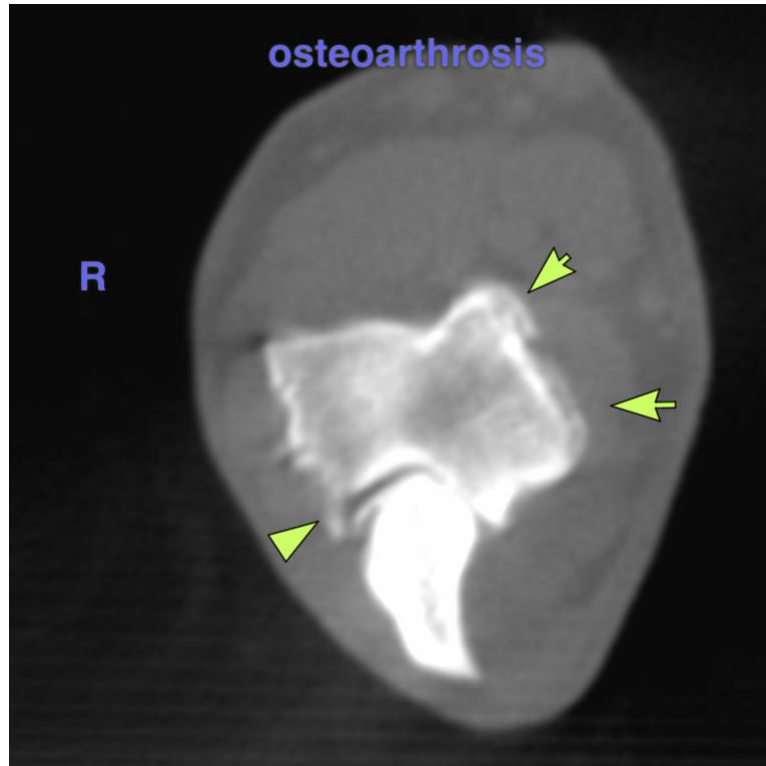Patricia Sanchez
Sanchez

INVOICE

72789

DATE

12-1-25





PATIENT

Henry Soloniewicz

SPECIES

Canine

BREED

Shih Tzu

SEX

MN

AGE

10

WEIGHT

8.1

INTERPRETED BY

Sebastian Schaub, DVM
Dr. med. vet.
DipECVDI

IMAGING PERFORMED BY

Patricia Sanchez
Sanchez

HOSPITAL NAME

Animal Trust - Bolton

REFERRING VET

Patricia Sanchez
Sanchez

INVOICE

72789

DATE

12-1-25

The information and recommendations provided are based on the images presented by the referring veterinarian/sonographer. No evaluation can be communicated regarding pathology that was not visible in the image/video clips provided.

Thank you for this referral. If the clinical or image interpretation does not parallel your findings or if I can be of any further assistance please contact me.

Sebastian Schaub, Sebastian Schaub, DVM, Dr. med. vet. DipECVDI
info@sonopath.com