

**PATIENT**

Brandi Lefevre

PRESENTING CLINICAL SIGNS

Suspect elbow dysplasia, specifically MCD.
Abnormal PE/Chem/CBC/UA Results: WNL

SPECIES

Canine

COMPUTED TOMOGRAPHY OF THE ELBOW JOINTS

A high resolution plain CT study of the elbow joints is provided for review.

BREED

Rottweiler X

COMPUTED TOMOGRAPHIC FINDINGS

The right elbow joint presents smooth osseous margins. The medial coronoid process of the right elbow joint is well defined with a homogeneous density, unremarkable. The joint space of the right elbow joint is congruent.

SEX

FS

The periarticular bones of the left elbow joint are smooth. The tip of the medial coronoid process of the left elbow joint is mildly irregular with a reduced irregular density. The joint space of the left elbow joint is congruent.

COMPUTED TOMOGRAPHIC DIAGNOSIS

- Pathology medial coronoid process left elbow joint
- Normal right elbow joint

AGE

11 Months

INTERPRETED BY

Sebastian Schaub, DVM
Dr. med. vet. DipECVDI

INTERPRETATION OF THE FINDINGS & FURTHER RECOMMENDATIONS

The findings indicate pathology of the medial coronoid process of the left elbow joint – suspect non-vital tip/cartilage flap – without a distinct osseous fragment. If the findings of the clinical examination support the diagnosis – pain can be elicited by pressure on the medial compartment of the left elbow joint – arthroscopy/arthrotomy to revise the elbow joint is recommended. If clinical examination indicates coronoid pathology of the right elbow joint as well, arthroscopy might be considered as well – in some cases negative CT study of the elbow joint does not rule out pathology entirely.

HOSPITAL NAME

Bridgwater
Veterinary Hospital
and Wellness Centre

REFERRING VET

Dr. C. Torevell

INVOICE

48728

DATE

12-1-21



PATIENT

Brandi Lefevre

SPECIES

Canine

BREED

Rottweiler X

SEX

FS

AGE

11 Months

INTERPRETED BY

Sebastian Schaub, DVM
Dr. med. vet. DipECVDI

HOSPITAL NAME

Bridgwater
Veterinary Hospital
and Wellness Centre

REFERRING VET

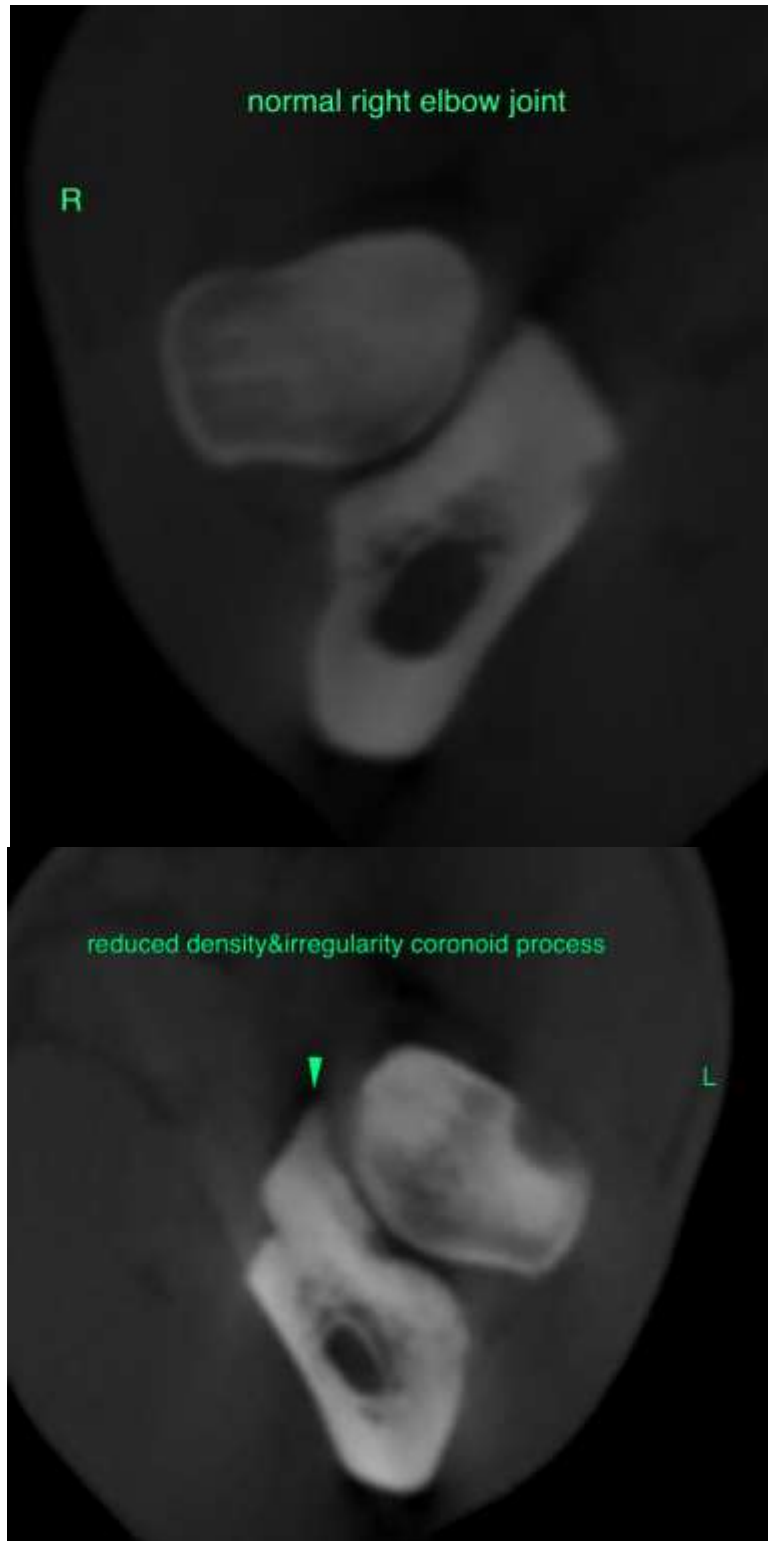
Dr. C. Torevell

INVOICE

48728

DATE

12-1-21





PATIENT

Brandi Lefevre

SPECIES

Canine

The information and recommendations provided are based on the images presented by the referring veterinarian. No evaluation can be communicated regarding pathology that was not visible in the image/video clips provided.

BREED

Rottweiler X

Thank you for this referral. If the clinical or image interpretation does not parallel your findings or if I can be of any further assistance please contact me.

Sebastian Schaub, Sebastian Schaub, DVM, Dr. med. vet. DipECVDI
sebast.schaub@gmail.com

SEX

FS

AGE

11 Months

INTERPRETED BY

Sebastian Schaub, DVM
Dr. med. vet. DipECVDI

HOSPITAL NAME

Bridgwater
Veterinary Hospital
and Wellness Centre

REFERRING VET

Dr. C. Torevell

INVOICE

48728

DATE

12-1-21