



**PATIENT**

Cher Burns

**PRESENTING CLINICAL SIGNS**

Patient presented with dry nonproductive cough, increasing in frequency from once every few weeks to once or twice a week to multiple coughing episodes per day.

**SPECIES**

Feline

**RADIOGRAPHIC STUDY OF THE THORAX**

Radiographs of the thorax in three imaging planes are provided for review.

**BREED**

DLH

The body condition score is 7-8/9.

The surrounding bony structures are within normal limits.

The extrathoracic soft tissues present homogeneous without abnormalities.

**SEX**

FS

The heart is of normal size and shape, there is no evidence of cardiac chamber or vascular enlargement. The pulmonary vasculature is within normal limits.

The cranial mediastinum and the pericardial sac are widened by fat.

**AGE**

12 Years, 6 Months

The trachea is normal in diameter and presents the anticipated course. The luminal outline of the trachea is smooth.

Generalized mild increased visibility of the bronchial walls is appreciated.

**INTERPRETED BY**

Sebastian Schaub, DVM  
Dr. med. vet. DipECVDI

The lung parenchyma presents the expected architecture and opacity; the intrapulmonary vascular branching is seen up to the third order lung vessels.

The diaphragm is well delineated with even surface and the expected mild cranial bulging of the diaphragmatic cupola.

**HOSPITAL NAME**

Gentle Doctor Animal  
Hospital

**RADIOGRAPHIC DIAGNOSIS**

- Obesity
- Bronchial lung pattern without signs of air-trapping

**REFERRING VET**

Dr. Thomassen

**INTERPRETATION OF THE FINDINGS & FURTHER RECOMMENDATIONS**

The radiographic changes are highly suggestive for underlying feline bronchial disease ('feline asthma') which is commonly allergic in origin ± bacterial/Mycoplasma or viral superinfection. Depending on the development of the presenting clinical signs under empirical therapy, complementing management by an asthma inhaler might be beneficial. Lower airway sampling can be considered as advanced diagnostic tool as well.

**INVOICE**

55083

**DATE**

11-9-22



**PATIENT**

Cher Burns

**SPECIES**

Feline

**BREED**

DLH

**SEX**

FS

**AGE**

12 Years, 6 Months

**INTERPRETED BY**

Sebastian Schaub, DVM  
Dr. med. vet. DipECVDI

**HOSPITAL NAME**

Gentle Doctor Animal  
Hospital

**REFERRING VET**

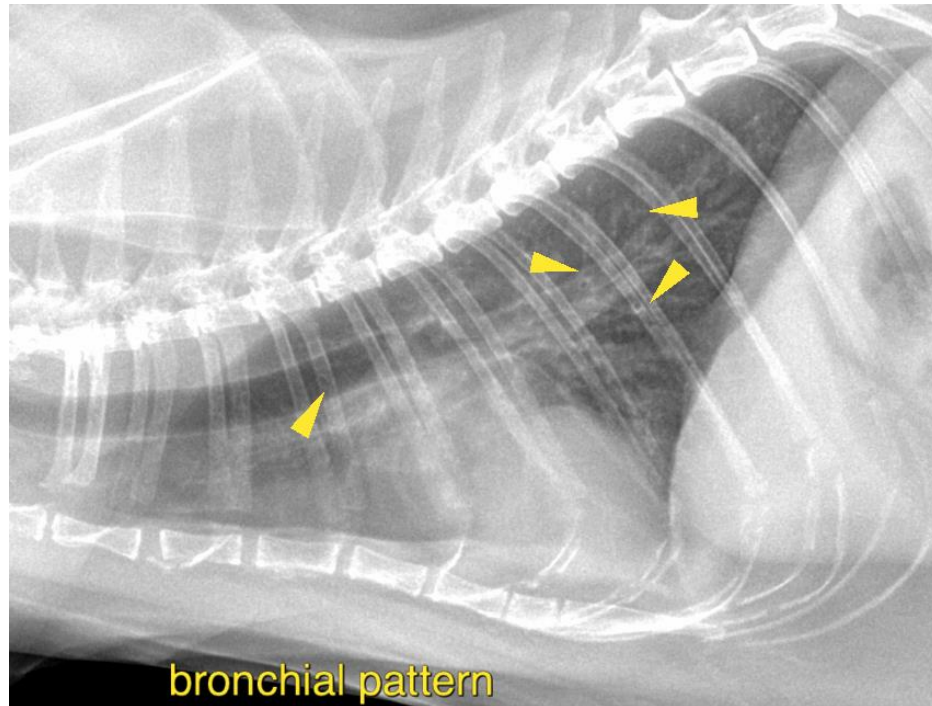
Dr. Thomassen

**INVOICE**

55083

**DATE**

11-9-22



The information and recommendations provided are based on the images presented by the referring veterinarian/sonographer. No evaluation can be communicated regarding pathology that was not visible in the image/video clips provided.

Thank you for this referral. If the clinical or image interpretation does not parallel your findings or if I can be of any further assistance please contact me.

**Sebastian Schaub**, Sebastian Schaub, DVM, Dr. med. vet. DipECVDI  
sebast.schaub@gmail.com