

PATIENT

Bane Lloyd

SPECIES

Feline

BREED

Sphynx

SEX

Neutered Male

AGE

2 Years

WEIGHT

8 Pounds

INTERPRETED BY

Sebastian Schaub,
DVM, Dr. med. vet.
DipECVDI

IMAGING PERFORMED BY

Mobile Pet Imaging

HOSPITAL NAME

Mobile Pet Imaging

REFERRING VET

Dr. Armstrong

INVOICE

35468

DATE

11/8/25

PRESENTING CLINICAL SIGNS

History: The pet has had nasal congestion and a cough since birth. DVM suspects polyps.

COMPUTED TOMOGRAPHIC STUDY OF THE SKULL & THORAX

A high resolution pre- and post-contrast CT study of the skull and a post-contrast CT study of the thorax is provided for review.

COMPUTED TOMOGRAPHIC FINDINGS

Skull

Multiple mandibular incisor teeth are absent.

The nasal cavity presents the expected aerated spaces between thin & even conchae and turbinates with smooth mucosal lining.

Both temporomandibular joints present congruent joint spaces with even subchondral bone surfaces and are considered within normal limits.

Both tympanic bullae are filled with non-contrast enhancing soft tissue material; the osseous wall is smooth and thin. The external ear canals are within normal limits.

The brain presents no deviation from normal anatomy and symmetry. The brain parenchyma is homogeneous and within normal limits for attenuation and distribution of contrast enhancement. The ventricular system is non-dilated and symmetric.

The mandibular lymph nodes are moderately prominent, uniform soft tissue attenuating and contrast enhancing; the short-to-long-axis ratio is maintained normal <0.5.

Thorax

The bony and surrounding soft tissue structures are within normal limits.

The sternal, cranial mediastinal and tracheobronchial lymph nodes are small elongated with a normal short-to-long-axis-ratio is < 0.5, the attenuation and contrast enhancement pattern is uniform and considered within normal limits.

The cardiovascular structures including the pulmonary vasculature are within normal limits.

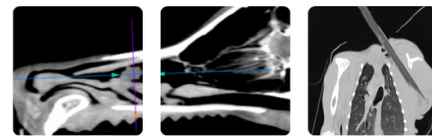
The bronchial tree presents with regular branching and tapers uniformly towards the periphery as expected, the bronchial walls are thin and smooth. The bronchus-to-artery ratio is within normal limits.

The lung parenchyma presents generalized decreased volume and mild to moderate ground glass attenuation pattern.

Small incidental gas pockets are seen within the esophageal lumen; there is no evidence of abnormal dilation.

COMPUTED TOMOGRAPHIC DIAGNOSIS

- Bilateral otitis media without inflammatory polyp formation



PATIENT

Bane Lloyd

- Lymphadenopathy mandibular lymph nodes
- Generalized unstructured interstitial lung pattern and mild decreased pulmonary volume
- Multiple absent mandibular incisor teeth

SPECIES

Feline

BREED

Sphynx

SEX

Neutered Male

AGE

2 Years

WEIGHT

8 Pounds

INTERPRETED BY

Sebastian Schaub,
DVM, Dr. med. vet.
DipECVDI

IMAGING PERFORMED BY

Mobile Pet Imaging

HOSPITAL NAME

Mobile Pet Imaging

REFERRING VET

Dr. Armstrong

INVOICE

35468

DATE

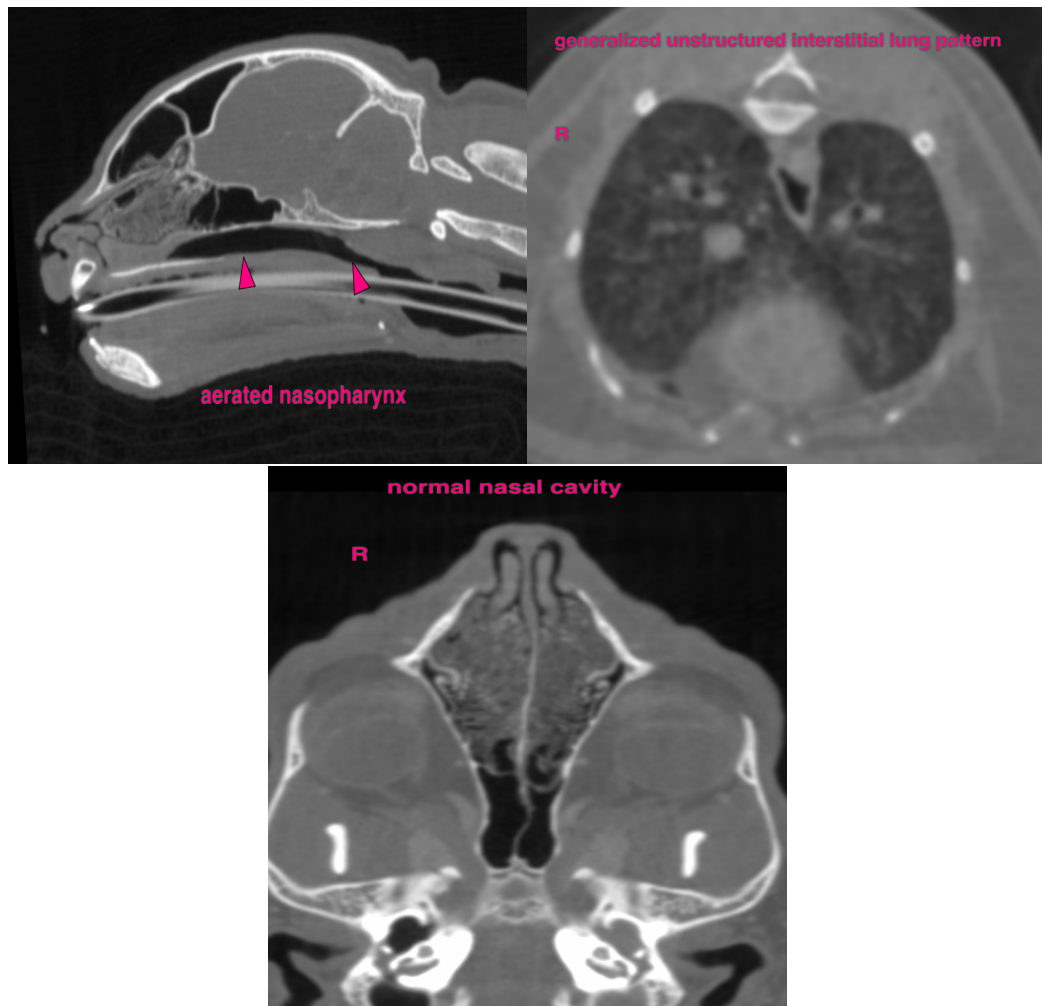
11/8/25

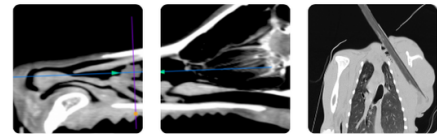
INTERPRETATION OF THE FINDINGS & FURTHER RECOMMENDATIONS

The CT study reveals no signs of active rhinitis nor mechanical upper airway obstruction. However, in combination with the described clinical signs, the odds for latent (viral) rhinitis with subsequent otitis media are high.

The prominent mandibular lymph nodes are consistent with reactive lymphoid hyperplasia, indicative for inflammatory process in the tributary region.

The unstructured interstitial lung pattern is likely accentuated by generalized hypoinflation of the lung parenchyma. Differential can include pneumonitis – allergic versus infectious (e.g. Mycoplasma) – or less likely fibrosis.





PATIENT

Bane Lloyd

SPECIES

Feline

BREED

Sphynx

SEX

Neutered Male

AGE

2 Years

WEIGHT

8 Pounds

INTERPRETED BY

Sebastian Schaub,
DVM, Dr. med. vet.
DipECVDI

**IMAGING
PERFORMED BY**

Mobile Pet Imaging

HOSPITAL NAME

Mobile Pet Imaging

REFERRING VET

Dr. Armstrong

INVOICE

35468

DATE

11/8/25

The information and recommendations provided are based on the images presented by the referring veterinarian/sonographer. No evaluation can be communicated regarding pathology that was not visible in the image/video clips provided.

Thank you for this referral. If the clinical or image interpretation does not parallel your findings or if I can be of any further assistance please contact me.

Sebastian Schaub, DVM, Dr. med. vet. DipECVDI
info@sonopath.com