



PATIENT

Mr. Kitty Lollipop
Nichols

PRESENTING CLINICAL SIGNS

Hyperthyroid patient Bigger bloated feel acting fine; maybe clingy urinates/pees a lot up in weight hairball/gurgling thorax radiographs looked unusual elevated white cell count

RADIOGRAPHIC STUDY OF THE THORAX & ABDOMEN

SPECIES

Feline

A complete set of radiographs of the thorax and abdomen is provided for review.

RADIOGRAPHIC FINDINGS

Thorax

BREED

DMH

The surrounding bony structures are within normal limits.

The extrathoracic soft tissues present homogeneous without abnormalities.

SEX

MN

The cardiac silhouette is elongated and has a mild 'banana shape'. The pulmonary vasculature is within normal limits.

The trachea is normal in diameter and presents the anticipated course. The luminal outline of the trachea is smooth.

AGE

16 Years, 11 Months

Generalized moderate peribronchial cuffing is appreciated.

The lung parenchyma presents the expected architecture and opacity; the intrapulmonary vascular branching is seen up to the third order lung vessels.

INTERPRETED BY

Sebastian Schaub, DVM
Dr. med. vet. DipECVDI

The diaphragm is well delineated with even surface and the expected mild cranial bulging of the diaphragmatic cupola.

Abdomen

Multifocal spondylosis formation is seen along vertebral endplates L1/I2 to L3/L4.

HOSPITAL NAME

Gentle Doctor Animal
Hospital

No abnormalities of the extraabdominal soft tissues are noted. The abdominal wall is smooth and thin.

The serosal detail is maintained throughout the peritoneal and retroperitoneal space.

The hepatic volume is mildly increased and the caudoventral margins are rounded.

REFERRING VET

Dr. Krapfl

The splenic head is in the anticipated position and within normal limits for size and opacity.

Both kidneys are seen and present with normal size, shape, delineation and opacity. The urinary bladder is significantly distended. No radiopaque calculi are noted throughout the upper and lower urinary tract.

INVOICE

55047

The stomach is in its anticipated position and presents normal content.

The small intestinal loops are of even diameter and non-dilated, a small amount of gas is seen within the small intestinal loops and considered within normal limits.

DATE

11-8-22

The colon is seen in the expected position and presents with appropriate content.



PATIENT

Mr. Kitty Lollipop
Nichols

SPECIES

Feline

BREED

DMH

SEX

MN

AGE

16 Years, 11 Months

INTERPRETED BY

Sebastian Schaub, DVM
Dr. med. vet. DipECVDI

HOSPITAL NAME

Gentle Doctor Animal
Hospital

REFERRING VET

Dr. Krapfl

INVOICE

55047

DATE

11-8-22

RADIOGRAPHIC DIAGNOSIS

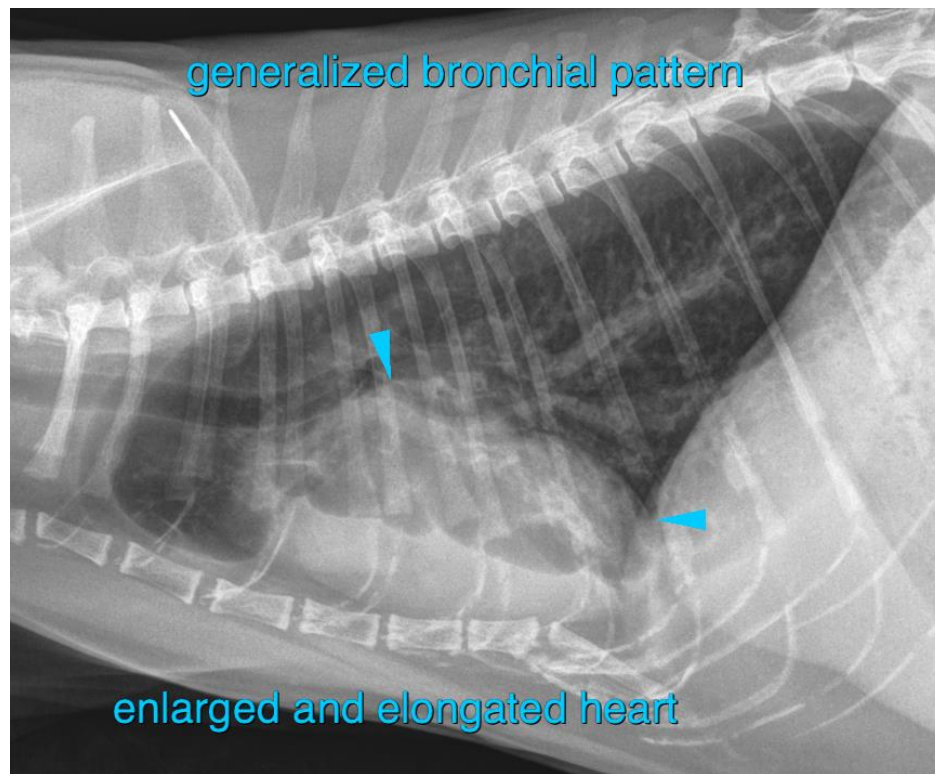
- Cardiomegaly
- Bronchial lung pattern
- Hepatomegaly
- Spondylosis deformans

INTERPRETATION OF THE FINDINGS & FURTHER RECOMMENDATIONS

The cardiomegaly in combination with the history of hyperthyroidism is concerning for accompanying (hypertrophic) cardiomyopathy. A cardiac echo can be used to screen for cardiac changes warranting medical management.

The bronchial lung pattern is compatible with bronchitis and due to the lack of history of preceding cough, I would consider the odds for infectious bronchitis – viral, bacterial, Mycoplasma, parasitic – higher than for allergic origin. Theoretically bronchial carcinoma can present with a bronchial pattern as well, but the odds are low.

Potentials for the hepatomegaly include metabolic hepatic disease/steroid induced hepatopathy, hepatitis or neoplastic infiltration. Ultrasound including FNA sampling can be used as minimally advanced diagnostic tests.





PATIENT

Mr. Kitty Lollipop
Nichols

SPECIES

Feline

The information and recommendations provided are based on the images presented by the referring veterinarian/sonographer. No evaluation can be communicated regarding pathology that was not visible in the image/video clips provided.

BREED

DMH

Thank you for this referral. If the clinical or image interpretation does not parallel your findings or if I can be of any further assistance please contact me.

Sebastian Schaub, Sebastian Schaub, DVM, Dr. med. vet. DipECVDI
sebast.schaub@gmail.com

SEX

MN

AGE

16 Years, 11 Months

INTERPRETED BY

Sebastian Schaub, DVM
Dr. med. vet. DipECVDI

HOSPITAL NAME

Gentle Doctor Animal
Hospital

REFERRING VET

Dr. Krapfl

INVOICE

55047

DATE

11-8-22