



PATIENT

Manson Bonderud

PRESENTING CLINICAL SIGNS

History of back pain. On 10/10/22 at exam: Squatted/hunched posture when walking, pain on palpation of the caudal thoracic spine and caudal lumbar spine. Negative proprioception on both back feet, motor intact, pain intact On Xray: Spondylosis in the lower thoracic (T13-L1, L1-L2, L2-L3 and lumbosacral (L6-L7 and L7-S1) spine and areas of radiolucency on the vertebral body of T11, T12, T13 on the lateral view. On the DV view, there are areas on the right side of the vertebral bodies of T11, T12, T13 there are areas of increased opacity. Abnormal PE/Chem/CBC/UA Results: Chemistry and CBC WNL

SPECIES

Canine

BREED

Boxer

COMPUTED TOMOGRAPHY OF THE CERVICAL, THORACIC AND LUMBAR SPINE

A high resolution plain and myelographic CT study of the entire spine is provided for review.

SEX

MN

COMPUTED TOMOGRAPHIC FINDINGS

In the right neuroforamen C6/C7 irregular mineralized material is seen. Post intrathecal contrast administration, mild protrusion of the intervertebral disc C6/C7 is noted, mildly depressing the ventral subarachnoid space at the same level.

AGE

10 Years, 4 Months

Multifocal spondylosis formation is seen along the thoracic and lumbar spine. Post intrathecal contrast administration, the spinal cord along the thoracic spine presents with smooth margins and the expected diameter.

INTERPRETED BY

Sebastian Schaub, DVM
Dr. med. vet. DipECVDI

A vacuum phenomenon is seen in the intervertebral disc space L2/L3. Post intrathecal contrast administration, a mild amount of material is seen in the right lateral aspect of the vertebral canal, mildly distorting the right subarachnoid space at the same level.

The lumbosacral intervertebral disc is protruding into the vertebral canal, occupying approximately 50% of the cross-sectional area of the vertebral canal at the same level. The vertebral endplates of the lumbosacral junction present advanced spondylosis formation - including the region of the neuroforamina.

HOSPITAL NAME

Casselton Vet Service

The first right rib presents with a chronic transverse fracture. The lung parenchyma presents multifocal pinpoint mineralization.

REFERRING VET

Dr. Brad Bartholomay

COMPUTED TOMOGRAPHIC DIAGNOSIS

- Right sided foraminal disc extrusion C6/C7
- Degenerative lumbosacral stenosis with lateral spondylosis formation and mild stenosis of the neuroforamina bilaterally
- Mild intervertebral disc protrusion L2/L3 without compressive myelopathy
- Chronic rib fracture right first rib
- Spondylosis deformans
- Pulmonary osteomas

INVOICE

55041

INTERPRETATION OF THE FINDINGS & FURTHER RECOMMENDATIONS

DATE

11-8-22

The right foraminal disc extrusion C6/C7 is likely chronic, and the clinical relevance is unclear, due to lack of pain along the cervical spine or right front limb lameness. The remainder of the changes appreciated along the thoracic and lumbar spine appear chronic and degenerative in nature and no abnormality can be specified, explaining the recent onset of pain - acute on chronic insult might be a potential.

There are no signs of aggressive bone lesions.



PATIENT

Manson Bonderud

SPECIES

Canine

BREED

Boxer

SEX

MN

AGE

10 Years, 4 Months

INTERPRETED BY

Sebastian Schaub, DVM
Dr. med. vet. DipECVDI

HOSPITAL NAME

Casselton Vet Service

REFERRING VET

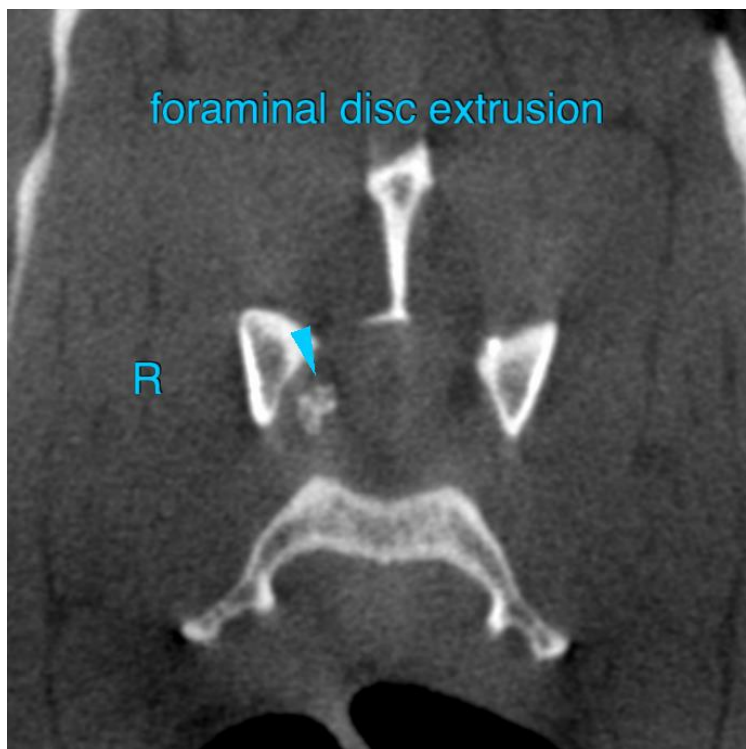
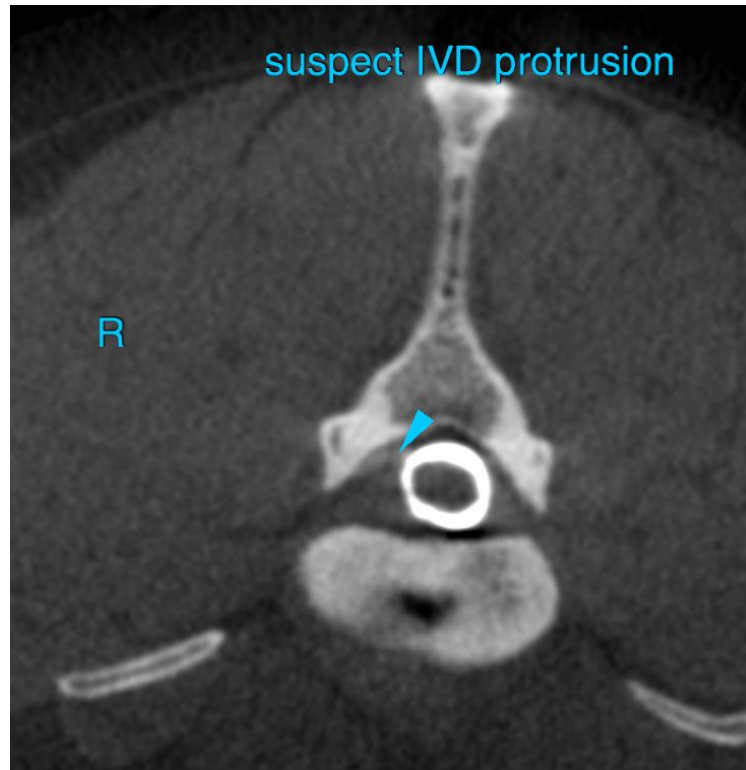
Dr. Brad Bartholomay

INVOICE

55041

DATE

11-8-22





PATIENT

Manson Bonderud

SPECIES

Canine

BREED

Boxer

SEX

MN

AGE

10 Years, 4 Months

INTERPRETED BY

Sebastian Schaub, DVM
Dr. med. vet. DipECVDI

HOSPITAL NAME

Casselton Vet Service

REFERRING VET

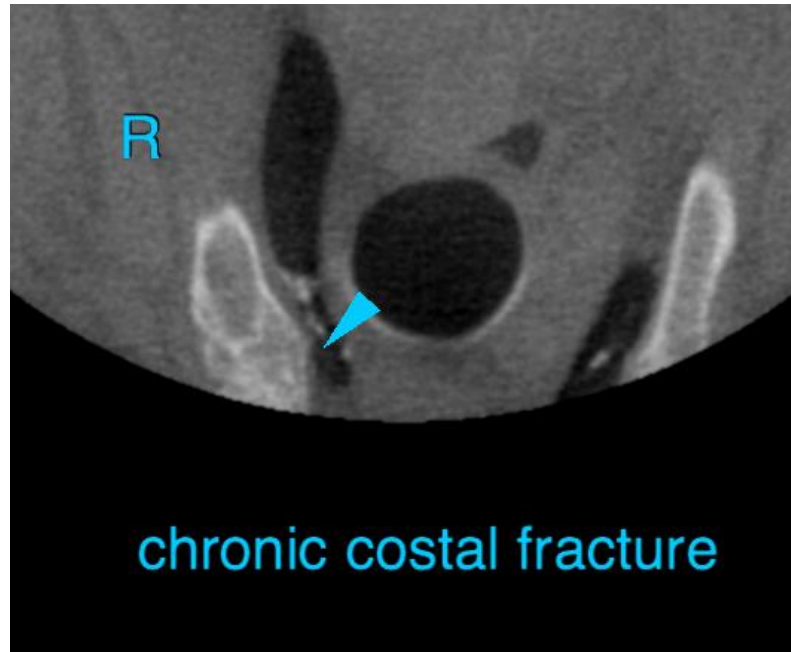
Dr. Brad Bartholomay

INVOICE

55041

DATE

11-8-22



The information and recommendations provided are based on the images presented by the referring veterinarian/sonographer. No evaluation can be communicated regarding pathology that was not visible in the image/video clips provided.

Thank you for this referral. If the clinical or image interpretation does not parallel your findings or if I can be of any further assistance please contact me.

Sebastian Schaub, Sebastian Schaub, DVM, Dr. med. vet. DipECVDI
sebast.schaub@gmail.com