



**PATIENT**

Luke Skywalker  
Shihideh

**PRESENTING CLINICAL SIGNS**

HX of chylothorax for 3-4 years. was treated medically. we performed an lymphangiography .  
Sent pre and post images

**COMPUTED TOMOGRAPHY OF THE THORAX AND ABDOMEN**

**SPECIES**

Canine

A high resolution plain CT study of the abdomen and a plain CT study and lymphangiography of the thorax are provided for review.

**COMPUTED TOMOGRAPHIC FINDINGS**

**BREED**

Shiba Inu

Thorax

The bony and surrounding soft tissue structures are within normal limits.

In the pleural cavity, a moderate amount of gravity, dependent, non-contrast enhancing soft tissue attenuating material is present. Pleural fissure lines are appreciated. The lung lobes are retracted from the thoracic wall and present a generalized decreased volume. Multiple regions with dystelectasis of the lung parenchyma are visible. A small amount of free gas is seen in the pleural cavity.

**SEX**

MN

**AGE**

5 Years

The cranial mediastinal lymph nodes are prominent.. In the lymphangiogram, level with T13, the thoracic duct is locate at the right lateral aspect of the aorta and a small collateral is seen at the dorsal aspect of the aorta. Level with T11 the thoracic duct is dividing into 3 branches with one small branch being located at the left laterodorsal aspect of the aorta.

**INTERPRETED BY**

Sebastian Schaub, DVM  
Dr. med. vet. DipECVDI

The bronchial tree presents with regular branching and tapers uniformly towards the periphery as expected, the bronchial walls are thin and smooth. The bronchus-to-artery ratio is within normal limits.

The lung parenchyma presents the expected architecture and attenuation behavior.

**HOSPITAL NAME**

Animal Surgical  
Center

Small incidental gas pockets are seen within the esophageal lumen, there is no evidence of abnormal dilation.

Abdomen

The serosal fat presents normal attenuation behavior. There is no evidence of peritoneal effusion or peritonitis.

**REFERRING VET**

Huntington Village  
Animal Hospital

Both kidneys present within normal limits for size, shape and organ architecture.

The adrenal glands are within normal limits for size, shape and organ architecture.

Both liver and spleen present with normal shape, even surface, uniformly attenuating parenchyma.

**INVOICE**

55070

The pancreas is evenly contoured, the pancreatic parenchyma is homogeneous.

The position, delineation, wall and content of the gastrointestinal tract are considered within normal limits throughout.

**DATE**

11-8-22

The bony and surrounding soft tissue structures reveal no abnormalities.



**PATIENT**

Luke Skywalker  
Shihideh

**COMPUTED TOMOGRAPHIC DIAGNOSIS**

- History of chronic chylothorax
- Mild pneumothorax – likely iatrogenic, due to preceding thoracocentesis
- Suspect reactive hyperplasia of the cranial mediastinal lymph nodes
- Normal abdomen

**SPECIES**

Canine

**INTERPRETATION OF THE FINDINGS & FURTHER RECOMMENDATIONS**

The CT study is fitting the history of chylothorax. If surgical management is an option, be aware of the multiple small branches of the thoracic duct being also locate on the left dorsolateral aspect of the aorta – best location for ligation appears to be level with T13.

**BREED**

Shiba Inu

**SEX**

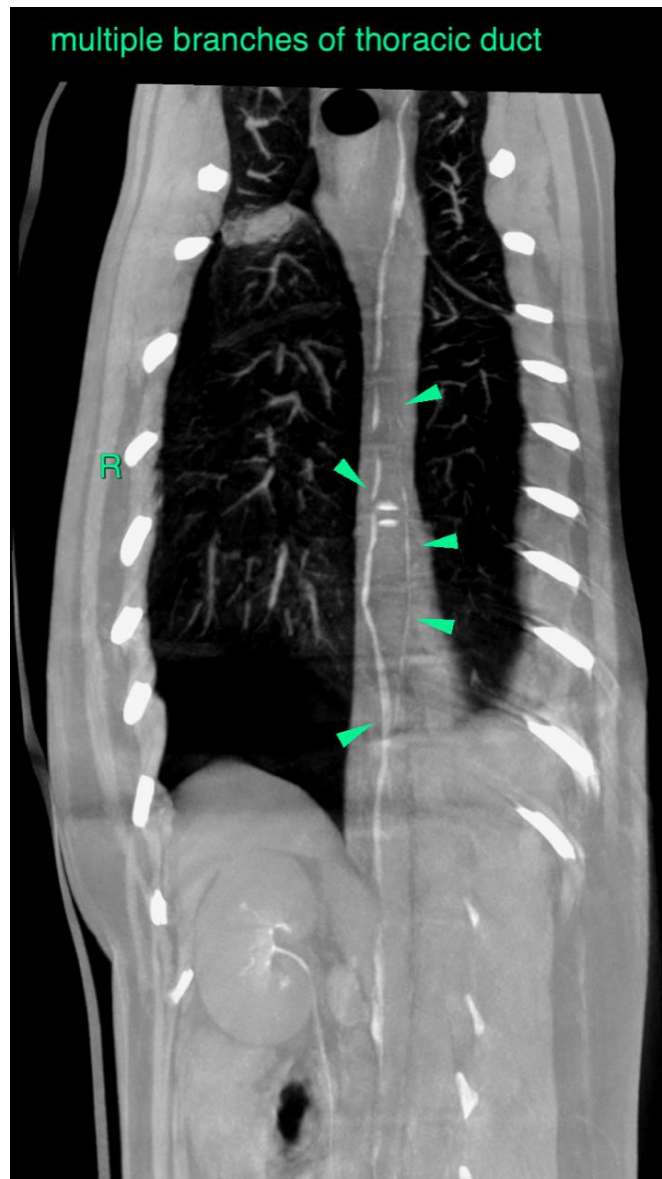
MN

**AGE**

5 Years

**INTERPRETED BY**

Sebastian Schaub, DVM  
Dr. med. vet. DipECVDI



**HOSPITAL NAME**

Animal Surgical  
Center

**REFERRING VET**

Huntington Village  
Animal Hospital

**INVOICE**

55070

**DATE**

11-8-22



**PATIENT**

Luke Skywalker  
Shihideh

**SPECIES**

Canine

**BREED**

Shiba Inu

**SEX**

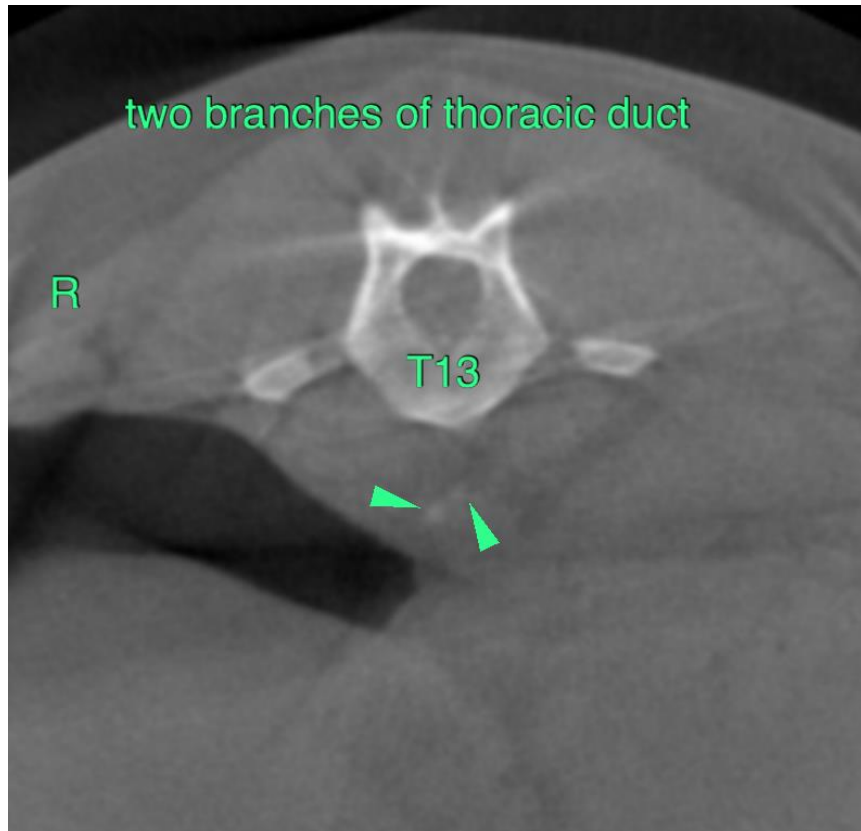
MN

**AGE**

5 Years

**INTERPRETED BY**

Sebastian Schaub, DVM  
Dr. med. vet. DipECVDI



**HOSPITAL NAME**

Animal Surgical  
Center

**REFERRING VET**

Huntington Village  
Animal Hospital

**INVOICE**

55070

**DATE**

11-8-22

The information and recommendations provided are based on the images presented by the referring veterinarian/sonographer. No evaluation can be communicated regarding pathology that was not visible in the image/video clips provided.

Thank you for this referral. If the clinical or image interpretation does not parallel your findings or if I can be of any further assistance please contact me.

**Sebastian Schaub**, Sebastian Schaub, DVM, Dr. med. vet. DipECVDI  
sebast.schaub@gmail.com