

PATIENT PRESENTING CLINICAL SIGNS

Bentley Edelstein Coughing, suspect lung mass.

COMPUTED TOMOGRAPHY OF THE THORAX AND ABDOMEN

SPECIES A high resolution pre- and post-contrast CT study of the thorax and abdomen are provided for review.

Canine **COMPUTED TOMOGRAPHIC FINDINGS**

Thorax

BREED The vertebral endplates T12/T13 present mild spondylosis formation

Goldendoodle The sternal, cranial mediastinal and tracheobronchial lymph nodes are small elongated with a normal short-to-long-axis-ratio is < 0.5, the attenuation and contrast enhancement pattern is uniform and considered within normal limits.

SEX The cardiovascular structures including the pulmonary vasculature are within normal limits.

Neutered Male In the right middle lung lobe, a mild irregular roundish, soft tissue attenuating peribronchial mass is appreciated, measuring 3.3 x 2.6 x 4.8 cm in size. The bronchial segments associated with the mass are partially compressed. The remainder of the lung parenchyma present the expected architecture and attenuation behavior.

AGE 11 Years, 2 Months Small incidental gas pockets are seen within the esophageal lumen, there is no evidence of abnormal dilation.

Abdomen

INTERPRETED BY Sebastian Schaub, DVM Dr. med. vet. DipECVDI The serosal fat presents normal attenuation behavior. There is no evidence of peritoneal effusion or peritonitis.

HOSPITAL NAME Mobile Pet Imaging The left kidney presents a convex bulging of the dorsal margin and at the same level a post contrast well-defined hypoattenuating lesion is protruding beyond the renal surface, measuring 1.6 cm in size.

The adrenal glands are within normal limits for size, shape and organ architecture.

Both liver and spleen present with normal shape, even surface, uniformly attenuating parenchyma and homogeneous contrast enhancement, unremarkable.

REFERRING VET Meaux The pancreas is evenly contoured, the pancreatic parenchyma is homogeneous and presents uniform contrast enhancement.

The position, delineation, wall and content of the gastrointestinal tract are considered within normal limits throughout.

INVOICE 55040 The vertebral endplates of the lumbosacral junction present moderate spondylosis formation. The lumbosacral intervertebral disc is protruding into the vertebral canal, occupying approximately 30% of the cross-sectional area of the vertebral canal at the same level.

DATE 11-8-22 There is an intramuscular lipoma within the craniodorsal aspect of the left abdominal wall, at the caudal aspect of the 13th left rib, extending caudally up to the level of L3.

The periarticular bones of the coxofemoral joints present mild osteophyte new bone formation.



PATIENT COMPUTED TOMOGRAPHIC DIAGNOSIS

- Bentley Edelstein
- Solitary pulmonary mass right middle lung lobe
 - Renal cyst left kidney
 - Degenerative lumbosacral stenosis with possible dynamic compression of the cauda equina fibers
 - Mild degenerative osteoarthritis coxofemoral joints bilaterally
 - Spondylosis deformans

SPECIES

Canine

INTERPRETATION OF THE FINDINGS & FURTHER RECOMMENDATIONS

BREED

Goldendoodle

The CT study is confirming the diagnosis of a pulmonary mass of the right middle lung lobe and primary pulmonary neoplasia is the first differential here – bronchogenic carcinoma is likely. A differential is granuloma, but the odds appear low. Ultrasound guided FNA sampling of the pulmonary mass can be performed as advanced diagnostic test to confirm the diagnosis. Complete surgical resection of the mass by lobectomy of the right middle lung lobe is considered feasible. There is no evidence of metastatic disease.

SEX

Neutered Male

AGE

11 Years, 2 Months

INTERPRETED BY

Sebastian Schaub, DVM
Dr. med. vet. DipECVDI

HOSPITAL NAME

Mobile Pet Imaging

REFERRING VET

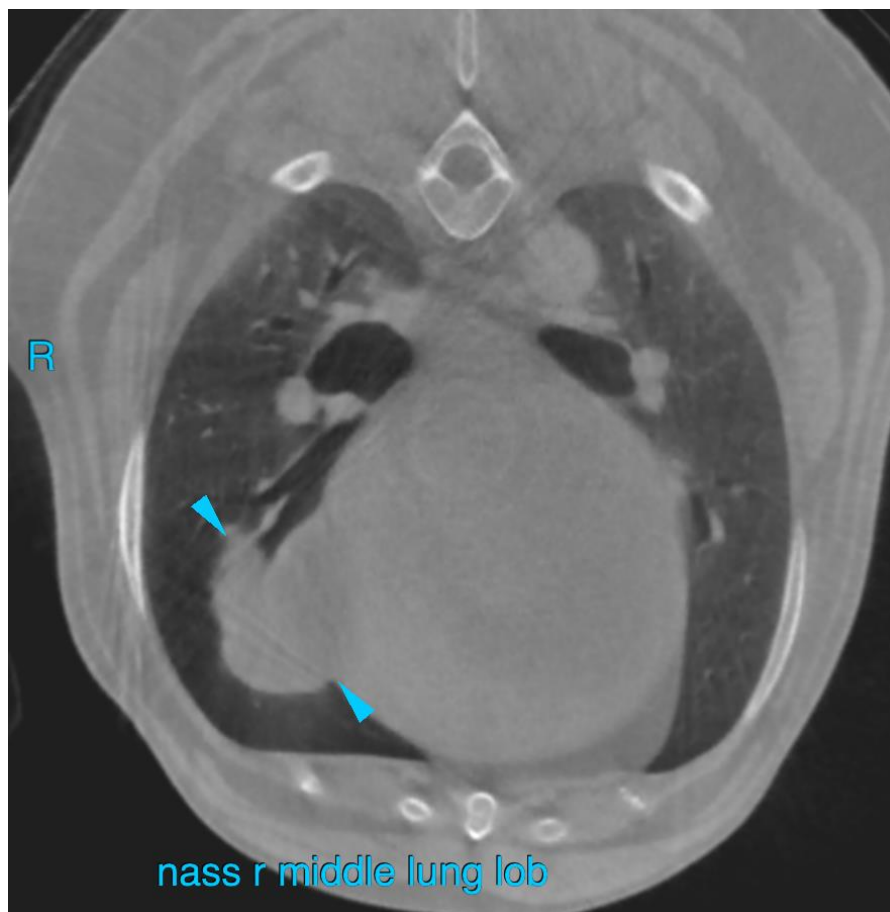
Meaux

INVOICE

55040

DATE

11-8-22





PATIENT

Bentley Edelstein

SPECIES

Canine

BREED

Goldendoodle

SEX

Neutered Male

AGE

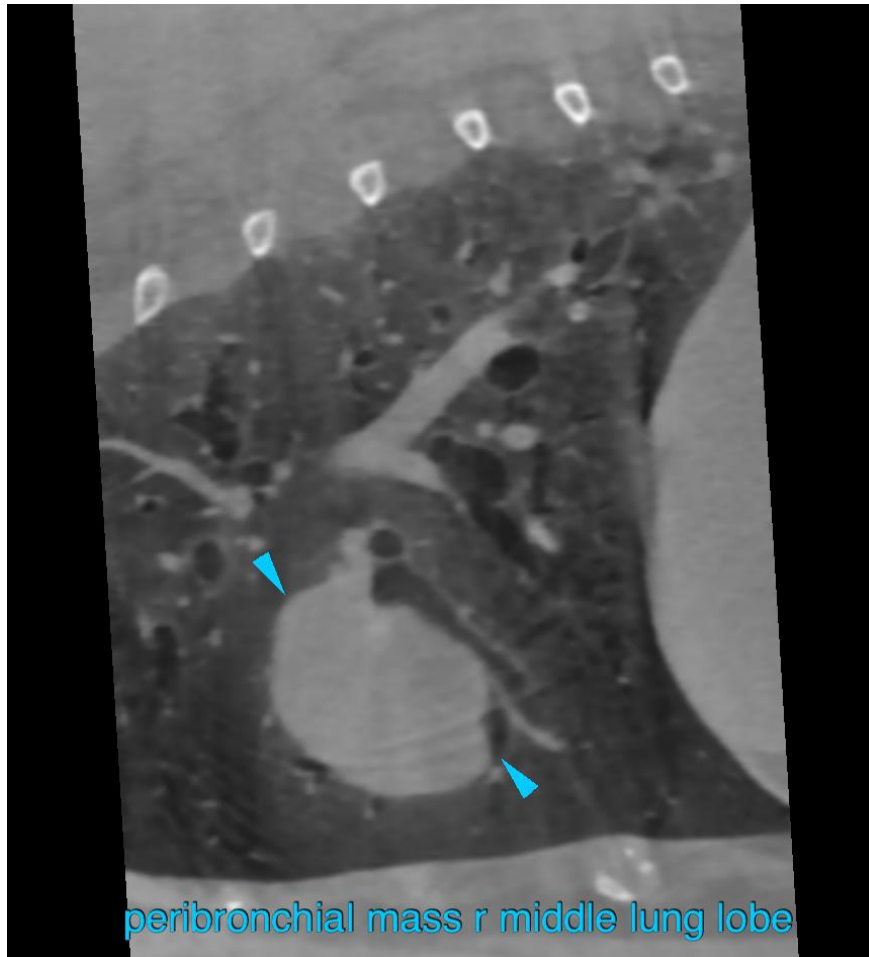
11 Years, 2 Months

INTERPRETED BY

Sebastian Schaub, DVM
Dr. med. vet. DipECVCI

HOSPITAL NAME

Mobile Pet Imaging



REFERRING VET

Meaux

INVOICE

55040

DATE

11-8-22

The information and recommendations provided are based on the images presented by the referring veterinarian/sonographer. No evaluation can be communicated regarding pathology that was not visible in the image/video clips provided.

Thank you for this referral. If the clinical or image interpretation does not parallel your findings or if I can be of any further assistance please contact me.

Sebastian Schaub, Sebastian Schaub, DVM, Dr. med. vet. DipECVCI
sebast.schaub@gmail.com