



PATIENT

Felipe Pollen

PRESENTING CLINICAL SIGNS

Felipe has had many episodes of reverse sneezing and increased nasal discharge for the last month. On exam, Felipe is panting and has slightly raspy breaths but no signs of respiratory distress, crackles or wheezes on exam. Concern for possible collapsing trachea.

SPECIES

Canine

RADIOGRAPHIC STUDY OF THE THORAX

Radiographs of the thorax in three imaging planes are provided for review.

BREED

Havanese

RADIOGRAPHIC FINDINGS

The surrounding bony structures are within normal limits.

The extrathoracic soft tissues present homogeneous without abnormalities.

The heart is of normal size and shape, there is no evidence of cardiac chamber or vascular enlargement. The pulmonary vasculature is within normal limits.

SEX

MN

The cranial mediastinum presents the expected soft tissue opacity. The mediastinal width is less than twice the width of the vertebral column at the same level.

AGE

15 Years

A soft tissue membrane is bulging ventrally into the lumen of the cervical segment of the trachea.

The bronchial tree presents with thin walls and tapers uniformly towards the periphery as expected.

INTERPRETED BY

Sebastian Schaub, DVM
Dr. med. vet. DipECVCI

The lung parenchyma presents the expected architecture and opacity; the intrapulmonary vascular branching is seen up to the third order lung vessels.

The diaphragm is well delineated with even surface and the expected mild cranial bulging of the diaphragmatic cupola.

HOSPITAL NAME

Gentle Doctor Animal
Hospital

RADIOGRAPHIC DIAGNOSIS

- Redundant tracheal membrane
- Normal thorax

REFERRING VET

Dr. Rotthaus

INTERPRETATION OF THE FINDINGS & FURTHER RECOMMENDATIONS

The redundant tracheal membrane is likely an incidental finding, however can be a precursor for tracheal collapse – check if cough can be elicited by pressure on the cervical tracheal segment.

INVOICE

55032

DATE

11-7-22



PATIENT

Felipe Pollen

SPECIES

Canine

BREED

Havanese

SEX

MN

AGE

15 Years

INTERPRETED BY

Sebastian Schaub, DVM
Dr. med. vet. DipECVDI

HOSPITAL NAME

Gentle Doctor Animal
Hospital

REFERRING VET

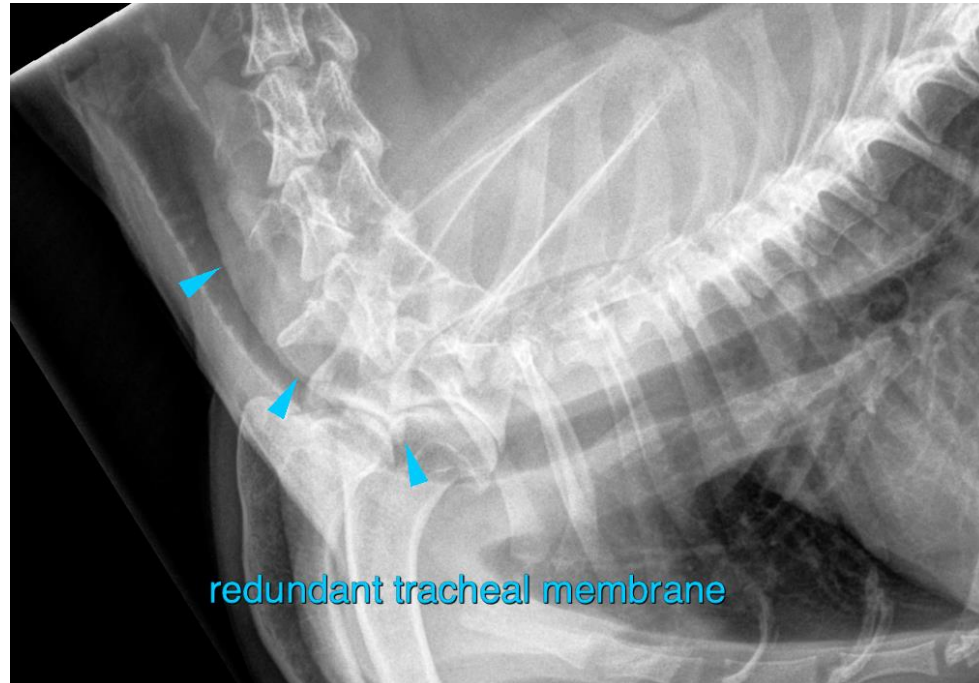
Dr. Rotthaus

INVOICE

55032

DATE

11-7-22



The information and recommendations provided are based on the images presented by the referring veterinarian/sonographer. No evaluation can be communicated regarding pathology that was not visible in the image/video clips provided.

Thank you for this referral. If the clinical or image interpretation does not parallel your findings or if I can be of any further assistance please contact me.

Sebastian Schaub, Sebastian Schaub, DVM, Dr. med. vet. DipECVDI
sebast.schaub@gmail.com