



PATIENT

Cooper Mccusker

PRESENTING CLINICAL SIGNS

front leg lameness for several weeks

SPECIES

Canine

COMPUTED TOMOGRAPHY OF THE FRONT LIMBS

A high resolution pre- and post-contrast CT study of the front limbs is provided for review.

BREED

Australian Shepherd

COMPUTED TOMOGRAPHIC FINDINGS

Centered on the proximal third of the left scapula a soft tissue attenuating and heterogeneous contrast enhancing ovoidal shaped mass is appreciated, bulging laterally into the subcutaneous tissue and medially into the subscapular region. Advanced permeative osteolysis of the proximal aspect of the left scapula and immature periosteal new bone formation is appreciated. The left scapular mass is measuring approximately 6.4 x 5.4 x 5.6 cm in size.

SEX

MN

The left axillary lymph node is prominent.

A soft tissue attenuating nodule is seen in the right middle lung lobe.

AGE

1 Year

COMPUTED TOMOGRAPHIC DIAGNOSIS

- Monostotic aggressive osteolytic lesion left proximal scapula
- Lymphadenopathy left axillary lymph node
- Solitary pulmonary nodule right middle lung

INTERPRETED BY

Sebastian Schaub, DVM
Dr. med. vet. DipECVDI

INTERPRETATION OF THE FINDINGS & FURTHER RECOMMENDATIONS

The aggressive bone lesion of the left scapula is consistent with primary osseous neoplasia and chondrosarcoma, juvenile osteosarcoma or hemangiosarcoma are considered as the top differentials here. FNA sampling of the mass can be used as advanced diagnostic tool. Complete surgical excision of the mass by (partial) scapulectomy is considered feasible. As primary osseous neoplasms of juvenile patients often present with high rate of metastatic spread, I consider the odds for metastasis to the left axillary lymph node and lung metastasis high.

HOSPITAL NAME

Animal Surgical
Center

REFERRING VET

Brookville Animal
Hospital

INVOICE

55022

DATE

11-7-22



PATIENT

Cooper Mccusker

SPECIES

Canine

BREED

Australian Shepherd

SEX

MN

AGE

1 Year

INTERPRETED BY

Sebastian Schaub, DVM
Dr. med. vet. DipECVDI

HOSPITAL NAME

Animal Surgical
Center

REFERRING VET

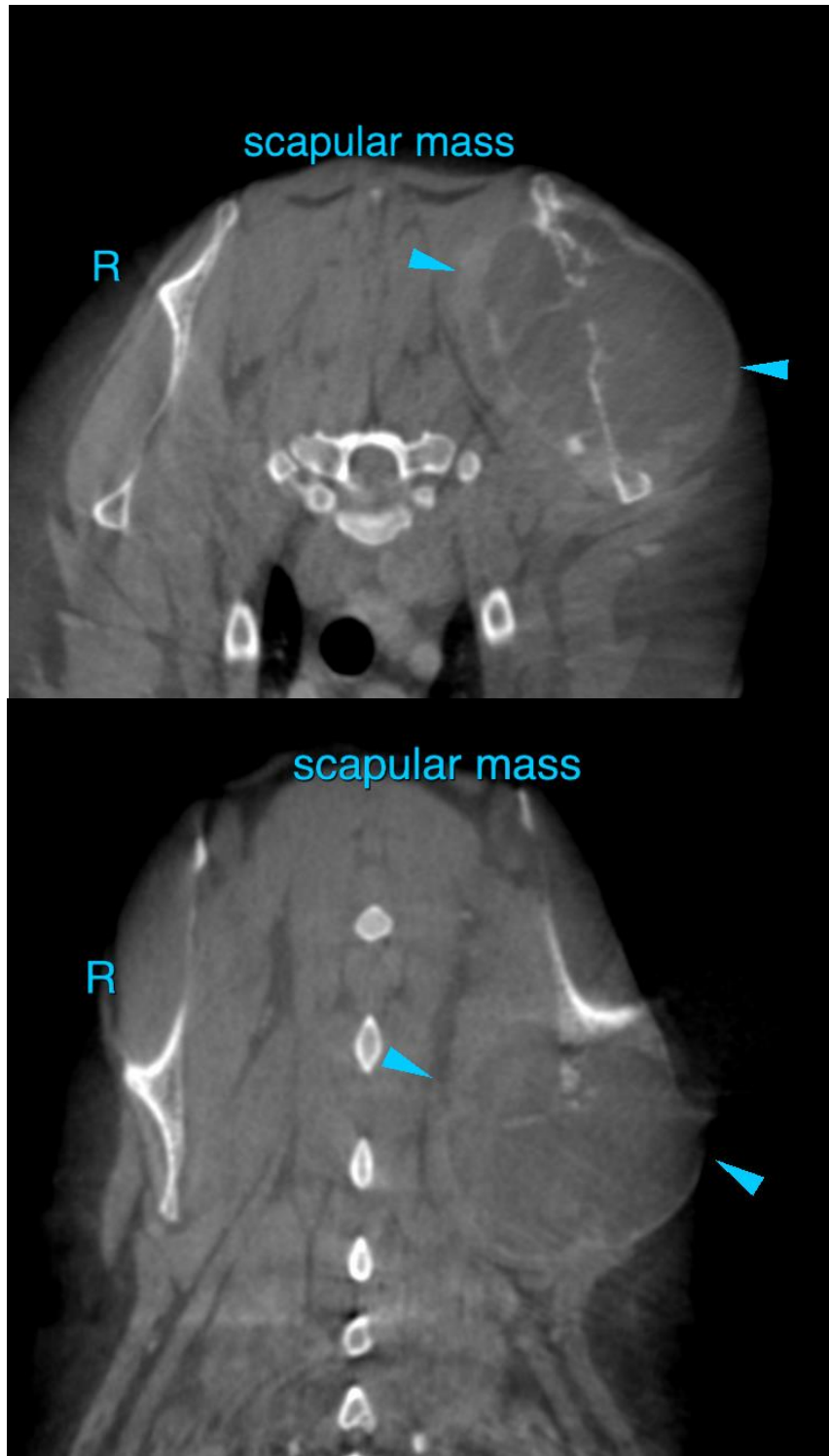
Brookville Animal
Hospital

INVOICE

55022

DATE

11-7-22





PATIENT

Cooper Mccusker

SPECIES

Canine

BREED

Australian Shepherd

SEX

MN

AGE

1 Year

INTERPRETED BY

Sebastian Schaub, DVM
Dr. med. vet. DipECVDI

HOSPITAL NAME

Animal Surgical
Center

REFERRING VET

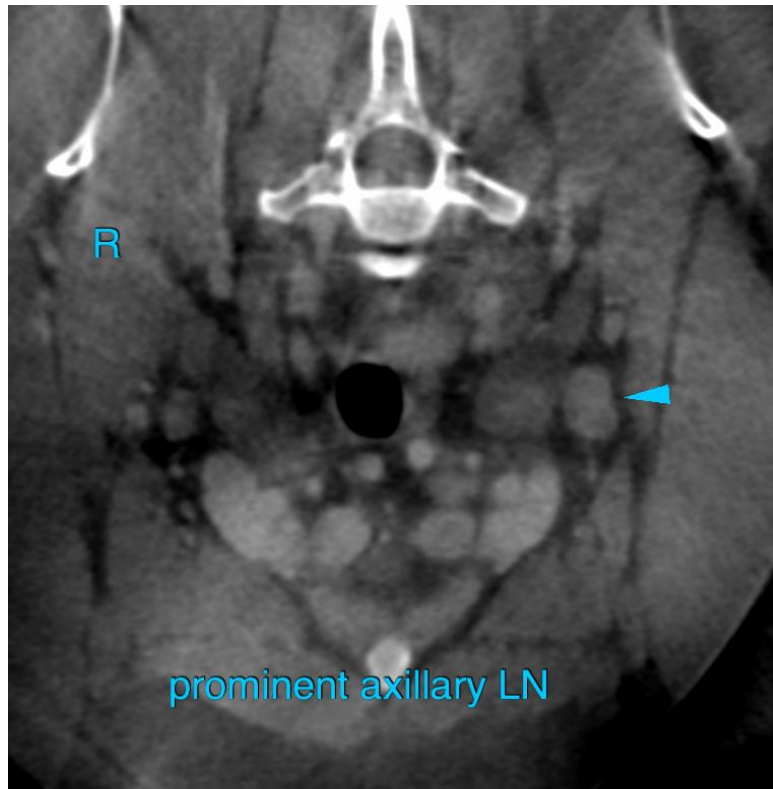
Brookville Animal
Hospital

INVOICE

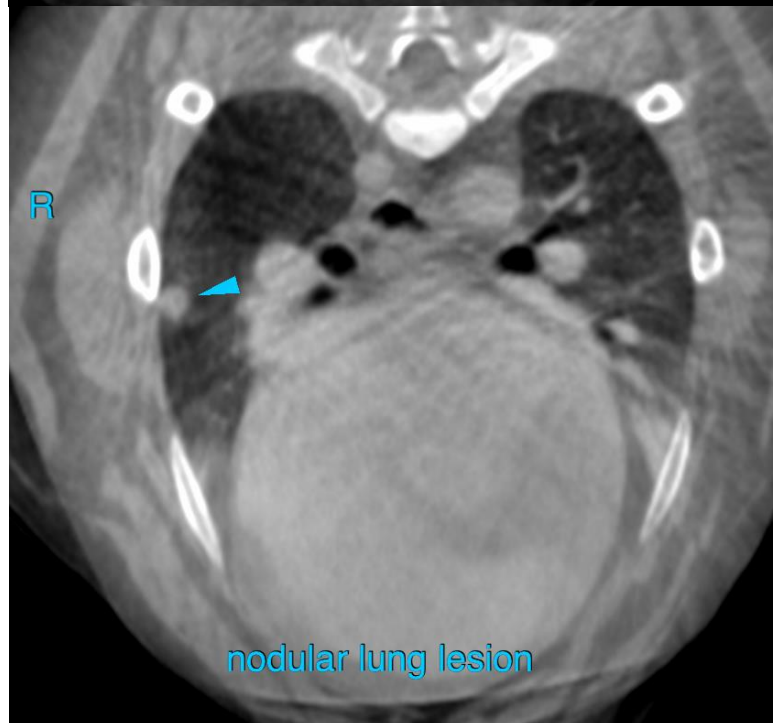
55022

DATE

11-7-22



prominent axillary LN



nodular lung lesion



PATIENT

Cooper Mccusker

The information and recommendations provided are based on the images presented by the referring veterinarian/sonographer. No evaluation can be communicated regarding pathology that was not visible in the image/video clips provided.

SPECIES

Canine

Thank you for this referral. If the clinical or image interpretation does not parallel your findings or if I can be of any further assistance please contact me.

Sebastian Schaub, Sebastian Schaub, DVM, Dr. med. vet. DipECVDI
sebast.schaub@gmail.com

BREED

Australian Shepherd

SEX

MN

AGE

1 Year

INTERPRETED BY

Sebastian Schaub, DVM
Dr. med. vet. DipECVDI

HOSPITAL NAME

Animal Surgical
Center

REFERRING VET

Brookville Animal
Hospital

INVOICE

55022

DATE

11-7-22