



PATIENT

Bob 2025 514 DAS

SPECIES

Feline

BREED

DSH

SEX

Neutered Male

AGE

2 Years

WEIGHT

4.5

INTERPRETED BY

Sebastian Schaub, DVM
Dr. med. vet. DipECVDI

IMAGING PERFORMED BY

Dr. Patricia Sanchez
Sanchez

HOSPITAL NAME

Animal Trust Bolton

REFERRING VET

Dr. Patricia Sanchez
Sanchez

INVOICE

35439

DATE

11/7/25

PRESENTING CLINICAL SIGNS

History: Chronic lameness LFL

COMPUTED TOMOGRAPHIC STUDY OF THE SHOULDER & ELBOW JOINTS

A high resolution pre- and post-contrast CT study of the front limbs is provided for review.

COMPUTED TOMOGRAPHIC FINDINGS

Both shoulder joints present smooth margins of the periarticular bones and the surrounding soft tissue structures are within normal limits.

The volume of the musculature of the left front limb is mild to moderately decreased.

Both elbow joints present smooth margins of the periarticular bones. The medial coronoid process of the elbow joints is well-defined and has a homogeneous density.

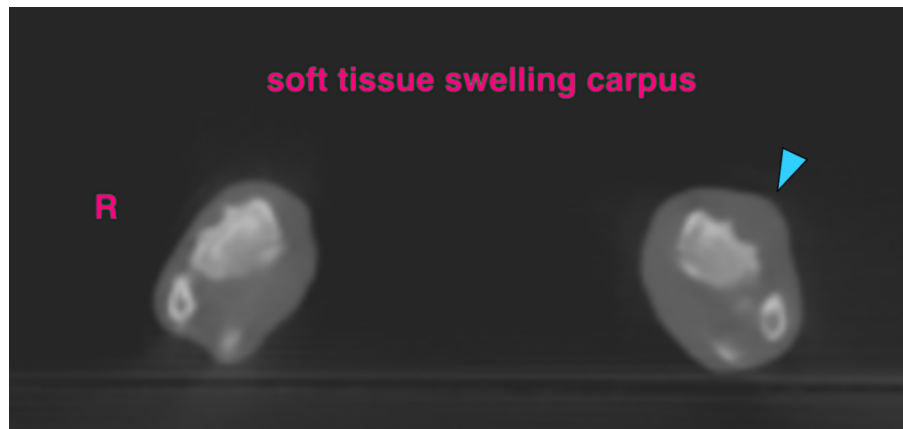
Dorsal to the left carpal joint, a uniform soft tissue swelling is appreciated.

COMPUTED TOMOGRAPHIC DIAGNOSIS

- Soft tissue swelling dorsal aspect left carpus
- Disuse atrophy musculature left front limb
- Normal shoulder joints
- Normal elbow joints

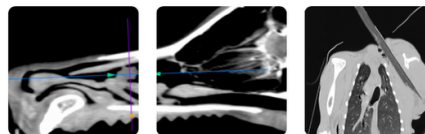
INTERPRETATION OF THE FINDINGS & FURTHER RECOMMENDATIONS

The main finding is the soft tissue swelling dorsal to the left carpal joint – concerning for arthritis, cellulitis or tenosynovitis. Ultrasound of the respective region can be performed for specification.



The information and recommendations provided are based on the images presented by the referring veterinarian/sonographer. No evaluation can be communicated regarding pathology that was not visible in the image/video clips provided.

Thank you for this referral. If the clinical or image interpretation does not parallel your findings or if I can be of any further assistance please contact me.



PATIENT

Bob 2025 514 DAS

Sebastian Schaub, DVM, Dr. med. vet. DipECVDI

info@sonopath.com

SPECIES

Feline

BREED

DSH

SEX

Neutered Male

AGE

2 Years

WEIGHT

4.5

INTERPRETED BY

Sebastian Schaub, DVM
Dr. med. vet. DipECVDI

IMAGING PERFORMED BY

Dr. Patricia Sanchez
Sanchez

HOSPITAL NAME

Animal Trust Bolton

REFERRING VET

Dr. Patricia Sanchez
Sanchez

INVOICE

35439

DATE

11/7/25