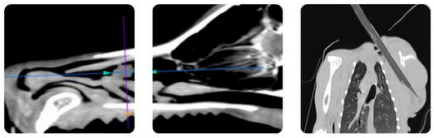

Teleradiology
Educational Teleconsultation Services™

PATIENT
Gracie Wild

SPECIES
Canine

BREED
Labrador Retriever

SEX
Female Spayed

AGE
4Y, 4M, 15D

WEIGHT
76.20lbs

INTERPRETED BY
Sebastian Schaub, DVM Dr. med. vet. DipECVDI

IMAGING PERFORMED BY
Joseph D'Abbraccio, DVM

HOSPITAL NAME
Catskill Veterinary Services, PLLC

REFERRING VET
Joseph D'Abbraccio, DVM

INVOICE
72529

DATE
11-5-25

PRESENTING CLINICAL SIGNS

Reason for Visit: Eye and ear issues, mass evaluation. History: Owner presented Gracie for concerns regarding her eyes and ears. Owner noted the right eye appears smaller and more partially closed compared to the left. Owner reported Gracie is not pawing at her face. Owner stated Gracie wakes them by flapping her ears but is not batting at her ears or head. Owner mentioned no ear cleaning has been done since prior medication was administered as recommended by Dr. Toso. Owner reported Gracie has not been allowed in water recently. Owner described a mass on the right inside area, previously treated with Benadryl for five days and a topical antibiotic. Owner stated cytology was performed and results were discussed, with prior mention of a possible round cell tumor. Owner reported that Gracie becomes panicked during nail trims and requested this be done while she is unconscious for procedures. Owner noted that after previous anesthesia, Gracie has experienced not feeling well, diarrhea, and persistent crying, and asked if anything could be done to mitigate these effects. Owner confirmed Gracie did not receive gabapentin or trazodone prior to the visit. C/S/V/D (Coughing, Sneezing, Vomiting, or Diarrhea): Owner reported Gracie has experienced diarrhea and not feeling well after previous anesthesia.
Abnormal PE/Chem/CBC/UA Results: PE: Eyes: OD: Smaller pupil, mild miosis, partial closure, weaker pupillary light response. OS: Clear, no discharge.; Ears: AD: Tympanic membrane mildly cloudy, slightly opaque. AS: Waxy debris. No pain or head shaking on exam.; Integument: Mass on the right inside forelimb; previously aspirated, cytology showed mixed inflammation with mild round cell proliferation, most consistent with benign histiocytoma. Mass on the thigh diagnosed as lipoma, non-malignant. CBC: Reticulocytes 134.8; Chem: WNL;

COMPUTED TOMOGRAPHY OF THE SKULL

A high resolution pre- and post-contrast CT study of the skull is provided for review.

COMPUTED TOMOGRAPHIC FINDINGS

The pictured parts of the dentition are complete and unremarkable in all jaw quadrants.

The nasal cavity presents the expected aerated spaces between thin & even conchae and turbinates with smooth mucosal lining.

The ocular bulbs have the same diameter of 2.1 cm. The anatomy of the ocular bulbs appears normal.

Both temporomandibular joints present congruent joint spaces with even subchondral bone surfaces and are considered within normal limits.

Both tympanic bullae are aerated, the mucosal lining is not seen, the bony wall is smooth and thin. The external ear canals are within normal limits.

The brain presents no deviation from normal anatomy and symmetry. The brain parenchyma is homogeneous and within normal limits for attenuation and distribution of contrast enhancement. The ventricular system is non-dilated and symmetric.

The submandibular and medial retropharyngeal lymph nodes are small and elongated with a normal short-to-long-axis-ratio is < 0.5, the attenuation and contrast enhancement pattern is uniform.

COMPUTED TOMOGRAPHIC DIAGNOSIS

- Normal skull
- No evidence of otitis externa nor media

PATIENT
Gracie Wild

SPECIES
Canine

BREED
Labrador Retriever

SEX
Female Spayed

AGE
4Y, 4M, 15D

WEIGHT
76.20lbs

INTERPRETED BY
Sebastian Schaub, DVM
Dr. med. vet.
DipECVDI

IMAGING PERFORMED BY
Joseph D'Abbraccio, DVM

HOSPITAL NAME
Catskill Veterinary Services, PLLC

REFERRING VET
Joseph D'Abbraccio, DVM

INVOICE
72529

DATE
11-5-25

INTERPRETATION OF THE FINDINGS & FURTHER RECOMMENDATIONS

The CT study of the skull reveals no abnormalities.

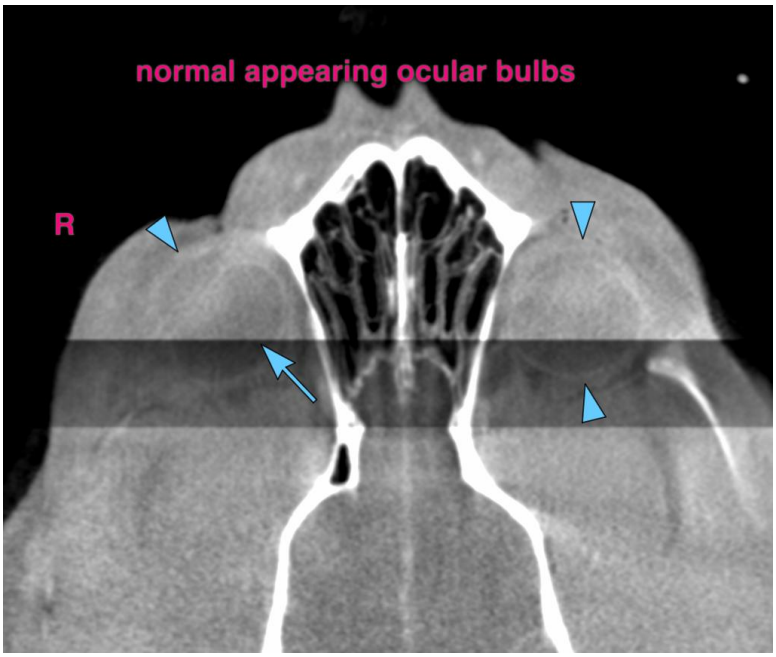

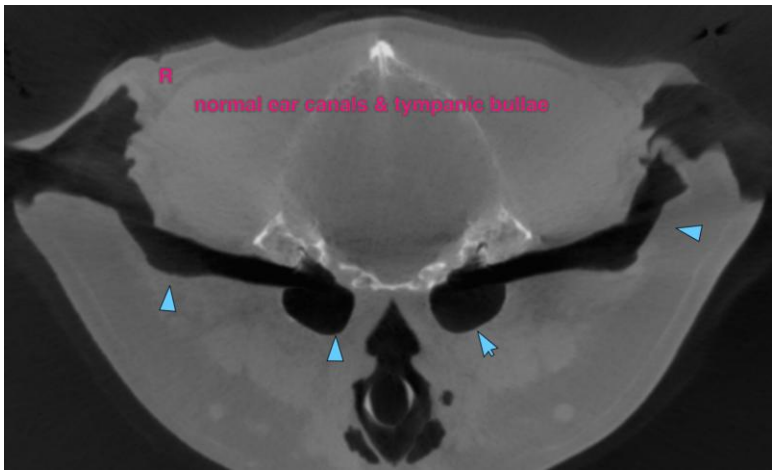

The information and recommendations provided are based on the images presented by the referring veterinarian/sonographer. No evaluation can be communicated regarding pathology that was not visible in the image/video clips provided.

Thank you for this referral. If the clinical or image interpretation does not parallel your findings or if I can be of any further assistance please contact me.

Sebastian Schaub, Sebastian Schaub, DVM, Dr. med. vet. DipECVDI
info@sonopath.com