

**PATIENT**

Maxx Peterson

PRESENTING CLINICAL SIGNS

MUSLE SPASMS IN HIS UPPER RIGHT SHOULDER/NECK AREA. PER O OCCASIONALLY SEEMS PAINFUL, PX WHIMPERS. NECK WILL GET STUCK TO THE RIGHT. WHEN IT HAS BEEN HAPPENING THEY WILL LIMIT HIS ACTIVITY FOR A FEW DAYS AND IT SEEMS TO HELP. WORSE THIS PAST WEEK. ON/OFF FOR 1.5+ YEARS, STARTED WITH LIMP ON RIGHT FRONT LEG.

SPECIES

Canine

COMPUTED TOMOGRAPHY OF THE NECK

A high resolution pre- and post-contrast CT study of the neck is provided for review.

BREED

Pointer Mix

COMPUTED TOMOGRAPHIC FINDINGS

A supernumerary triadan 405 is present.

SEX

MN

The vertebral endplates C3/C4 present mothaten osteolytic lesions destructing the surface of the subchondral bone. The intervertebral disc space C3/C4 is collapsed. The vertebral endplates present moderate ventral spondylosis formation.

AGE

2.5 Years

The soft tissue structures of the neck are within normal limits.

INTERPRETED BY

Sebastian Schaub, DVM
Dr. med. vet. DipECVDI

- Active discospondylitis C3/C4

INTERPRETATION OF THE FINDINGS & FURTHER RECOMMENDATIONS

The changes are consistent with discospondylitis C3/C4 likely secondary to hematogenous spread. Radiographs of the thoracic & lumbar spine can be used to screen if additional regions with discospondylitis are present. Recommend an abdominal ultrasound examination including a complete urinalysis ± radiographs of the thorax to check for potential infectious nidus. Pain management and long term antimicrobial therapy are indicated.

HOSPITAL NAME

Scottsdale Veterinary
Clinic

REFERRING VET

Dr. Gans

INVOICE

48268

DATE

11-5-21



PATIENT

Maxx Peterson

SPECIES

Canine

BREED

Pointer Mix

SEX

MN

AGE

2.5 Years

INTERPRETED BY

Sebastian Schaub, DVM
Dr. med. vet. DipECVDI

HOSPITAL NAME

Scottsdale Veterinary
Clinic

REFERRING VET

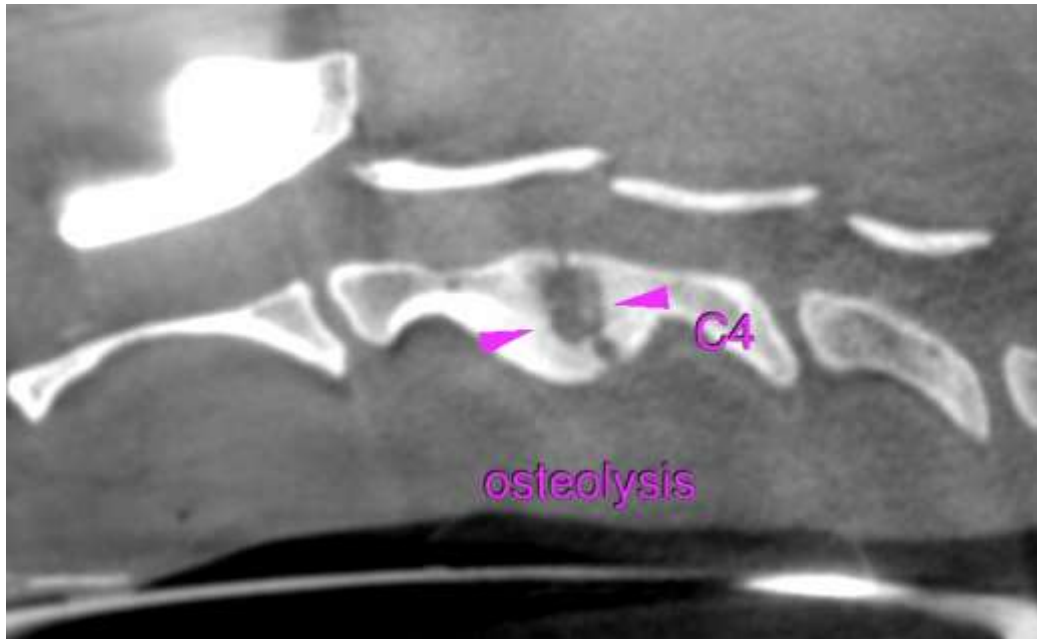
Dr. Gans

INVOICE

48268

DATE

11-5-21



The information and recommendations provided are based on the images presented by the referring veterinarian. No evaluation can be communicated regarding pathology that was not visible in the image/video clips provided.

Thank you for this referral. If the clinical or image interpretation does not parallel your findings or if I can be of any further assistance please contact me.

Sebastian Schaub, Sebastian Schaub, DVM, Dr. med. vet. DipECVDI
sebast.schaub@gmail.com