



PATIENT

Frida Hutcheson

PRESENTING CLINICAL SIGNS

pet seen for wellness exam, on P.E. newly diagnosed heart murmur, O has reported decreased activity but no cough, remainder of unremarkable for senior pet

SPECIES

Canine

RADIOGRAPHIC STUDY OF THE THORAX

Radiographs of the thorax in three imaging planes are provided for review.

BREED

Whippet

RADIOGRAPHIC FINDINGS

The surrounding bony structures are within normal limits.

SEX

FS

The heart is of normal size and shape, there is no evidence of cardiac chamber or vascular enlargement. The pulmonary vasculature is within normal limits.

AGE

12 Years

The cranial mediastinum presents the expected soft tissue opacity. The mediastinal width is less than twice the width of the vertebral column at the same level.

INTERPRETED BY

Sebastian Schaub, DVM
Dr. med. vet. DipECVDI

The bronchial tree presents with thin walls and tapers uniformly towards the periphery as expected.

The lung parenchyma presents the expected architecture and opacity; the intrapulmonary vascular branching is seen up to the third order lung vessels.

HOSPITAL NAME

Paws and Claws
Urgent Care

The diaphragm is well delineated with even surface and the expected mild cranial bulging of the diaphragmatic cupola.

RADIOGRAPHIC DIAGNOSIS

- Normal thorax

REFERRING VET

Dr. Juarez

INTERPRETATION OF THE FINDINGS & FURTHER RECOMMENDATIONS

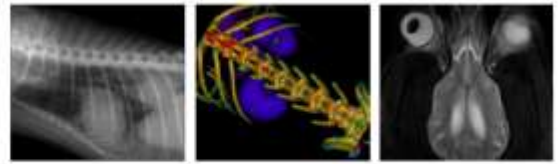
The radiographic study thorax presents no abnormalities. A cardiac echo might be used for further definition of the cardiac murmur.

INVOICE

48274

DATE

11-5-21



PATIENT

Frida Hutcheson

The information and recommendations provided are based on the images presented by the referring veterinarian. No evaluation can be communicated regarding pathology that was not visible in the image/video clips provided.

SPECIES

Canine

Thank you for this referral. If the clinical or image interpretation does not parallel your findings or if I can be of any further assistance please contact me.

BREED

Whippet

Sebastian Schaub, Sebastian Schaub, DVM, Dr. med. vet. DipECVDI
sebast.schaub@gmail.com

SEX

FS

AGE

12 Years

INTERPRETED BY

Sebastian Schaub, DVM
Dr. med. vet. DipECVDI

HOSPITAL NAME

Paws and Claws
Urgent Care

REFERRING VET

Dr. Juarez

INVOICE

48274

DATE

11-5-21