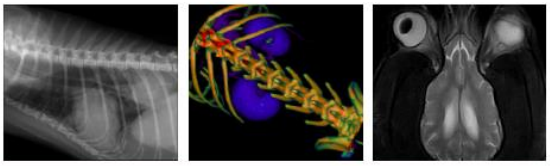

SonoPath.com
1-800-838-4268 info@sonopath.com

PATIENT

Elmo Law

SPECIES

Canine

BREED

Shih Tzu

SEX

Neutered Male

AGE

13 Years

INTERPRETED BY

Sebastian Schaub, DVM Dr. med. vet. DipECVDI

HOSPITAL NAME

Private Veterinary Specialties

REFERRING VET

Dr. Hamilton

INVOICE

14209

DATE

11/5/21

PRESENTING CLINICAL SIGNS

History: Lung Mass, Elmo has a history of heart disease. Recheck cardiology visit on 10.13.21 noted a mass in the left cranial lung lobe. This mass was not present the last time he had thoracic radiographs which was over a year ago. Prior to surgery a CT scan of the lungs can be performed to screen patients for spread of their tumor to local lymph nodes or other parts of the lungs.
Abnormal PE/Chem/CBC/UA Results:

COMPUTED TOMOGRAPHIC STUDY OF THE THORAX

A high resolution pre- and post-contrast CT study of the thorax is provided for review.

COMPUTED TOMOGRAPHIC FINDINGS

In the subcutaneous tissue dorsal to T6 to T8, an ovoid shaped, uniform soft tissue attenuating and mild contrast enhancing mass is visible, measuring 3.5 x 1.2 x 3.3 cm in size. A second small subcutaneous soft tissue nodule is seen caudal to the mass, measuring 3 mm in size.

The superficial cervical lymph nodes bilaterally are prominent.

The sternal, cranial mediastinal and tracheobronchial lymph nodes are small elongated with a normal short-to-long-axis-ratio is < 0.5, the attenuation and contrast enhancement pattern is uniform and considered within normal limits.

In the cranial part of the left cranial lung lobe, a well-defined, soft tissue attenuating and mild heterogeneous contrast enhancing roundish mass is visible measuring approximately 3.4 cm in diameter. The mass causes rounding of the margins of the lung at the same level. The mass is distorting and compressing the accompanying bronchi. The first-degree bronchus of the cranial part of the left cranial lung lobe presents marked thickening of the wall with stenosis of the lumen, extending up to the hilar region of the respective part of the lung lobe. The ventral dependent aspects of the lung presents multiple regions of dystelectasis.

Small incidental gas pockets are seen within the esophageal lumen, there is no evidence of abnormal dilation.

COMPUTED TOMOGRAPHIC DIAGNOSIS

- Soft tissue mass cranial part of left cranial lung lobe and bronchial circumferential mural thickening first degree bronchus of the cranial part left cranial lung lobe
- Multiple regions of dystelectasis of the lung
- Subcutaneous soft tissue mass dorsal to thoracic spine
- Lymphadenopathy superficial cervical lymph nodes

INTERPRETATION OF THE FINDINGS & FURTHER RECOMMENDATIONS

The findings are consistent with the history of a soft tissue mass originating from the cranial segment of the left cranial lung lobe and a mural mass of the respective first-degree bronchus. The top

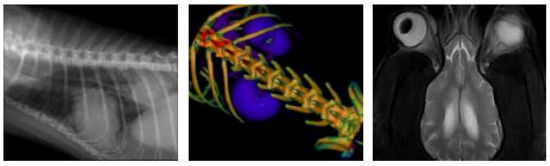

SonoPath.com
1-800-838-4268 info@sonopath.com

PATIENT

Elmo Law

SPECIES

Canine

BREED

Shih Tzu

SEX

Neutered Male

AGE

13 Years

INTERPRETED BY

Sebastian Schaub, DVM Dr. med. vet. DipECVDI

HOSPITAL NAME

Private Veterinary Specialties

REFERRING VET

Dr. Hamilton

INVOICE

14209

DATE

11/5/21

differential is bronchogenic/broncho-alveolar carcinoma. Complete surgical excision of the mass appears feasible, lobectomy of the complete left cranial lung lobe should be considered as the mural thickening is extending nearly up to the hilary region of the cranial segment of the left cranial lung lobe.
There is no evidence of pulmonary metastatic disease.
The prominent superficial cervical lymph nodes are most consistent with reactive hyperplasia, recommend FNA sampling to rule out neoplastic transformation.

FNA sampling of the subcutaneous mass dorsal to the thoracic spine can be performed as advanced minimally invasive test.

SonoPath Teleradiology

EDUCATIONAL TELECONSULTATION SERVICES™

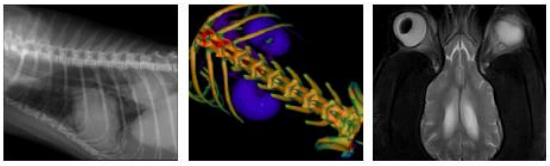

SonoPath.com
1-800-838-4268 info@sonopath.com

PATIENT

Elmo Law

SPECIES

Canine

BREED

Shih Tzu

SEX

Neutered Male

AGE

13 Years

INTERPRETED BY

Sebastian Schaub, DVM Dr. med. vet. DipECVDI

HOSPITAL NAME

Private Veterinary Specialties

REFERRING VET

Dr. Hamilton

INVOICE

14209

DATE

11/5/21

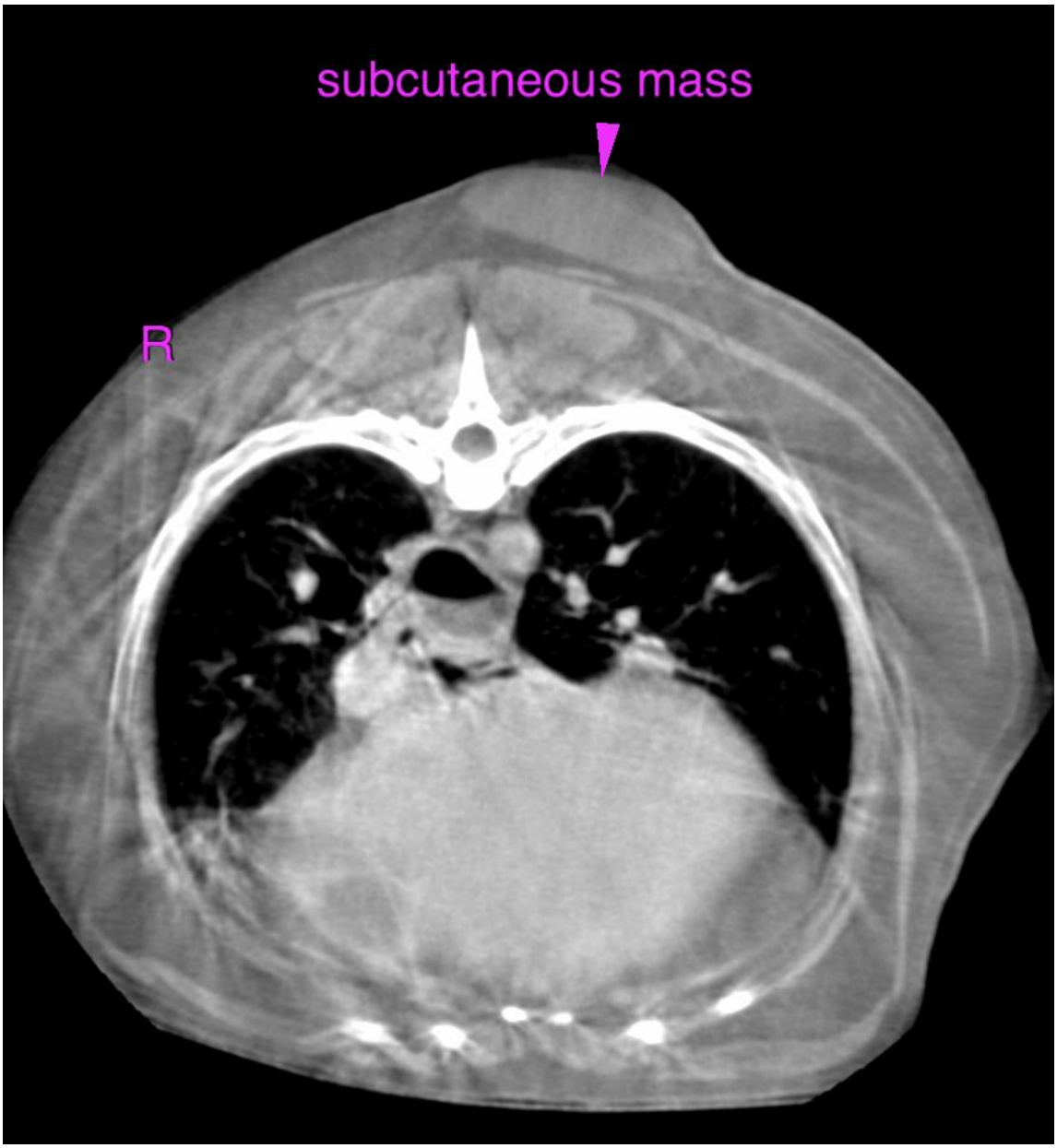

SonoPath Teleradiology

EDUCATIONAL TELECONSULTATION SERVICES™

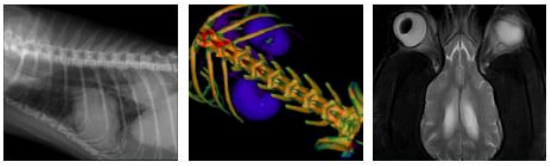

SonoPath.com
1-800-838-4268 info@sonopath.com

PATIENT

Elmo Law

SPECIES

Canine

BREED

Shih Tzu

SEX

Neutered Male

AGE

13 Years

INTERPRETED BY

Sebastian Schaub, DVM Dr. med. vet. DipECVDI

HOSPITAL NAME

Private Veterinary Specialties

REFERRING VET

Dr. Hamilton

INVOICE

14209

DATE

11/5/21

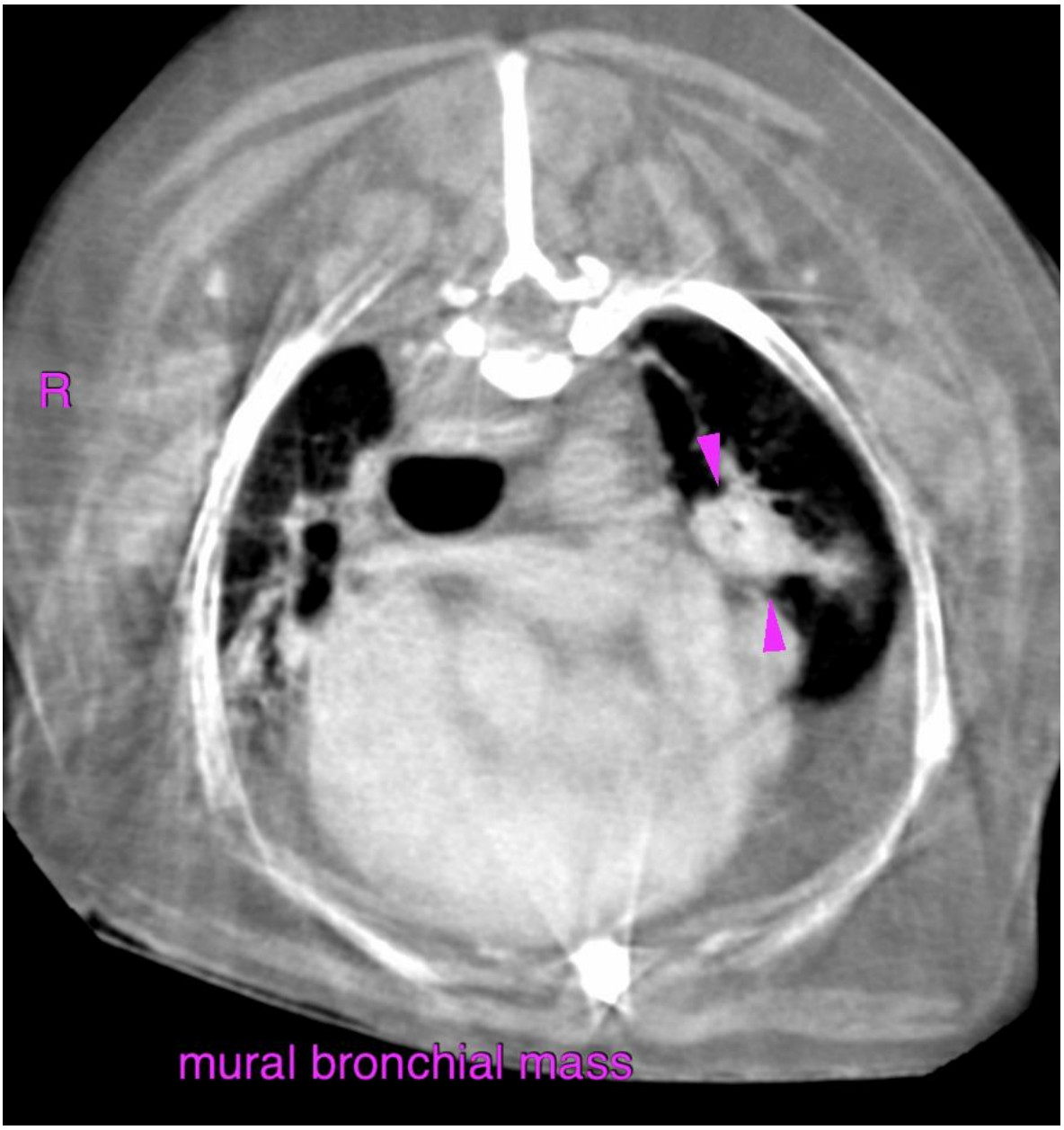

SonoPath Teleradiology

EDUCATIONAL TELECONSULTATION SERVICES™

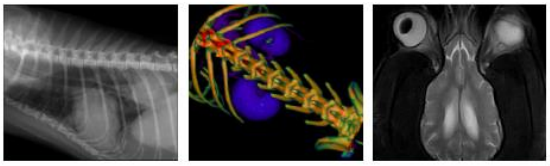

SonoPath.com
1-800-838-4268 info@sonopath.com

PATIENT

Elmo Law

SPECIES

Canine

BREED

Shih Tzu

SEX

Neutered Male

AGE

13 Years

INTERPRETED BY

Sebastian Schaub, DVM Dr. med. vet. DipECVDI

HOSPITAL NAME

Private Veterinary Specialties

REFERRING VET

Dr. Hamilton

INVOICE

14209

DATE

11/5/21

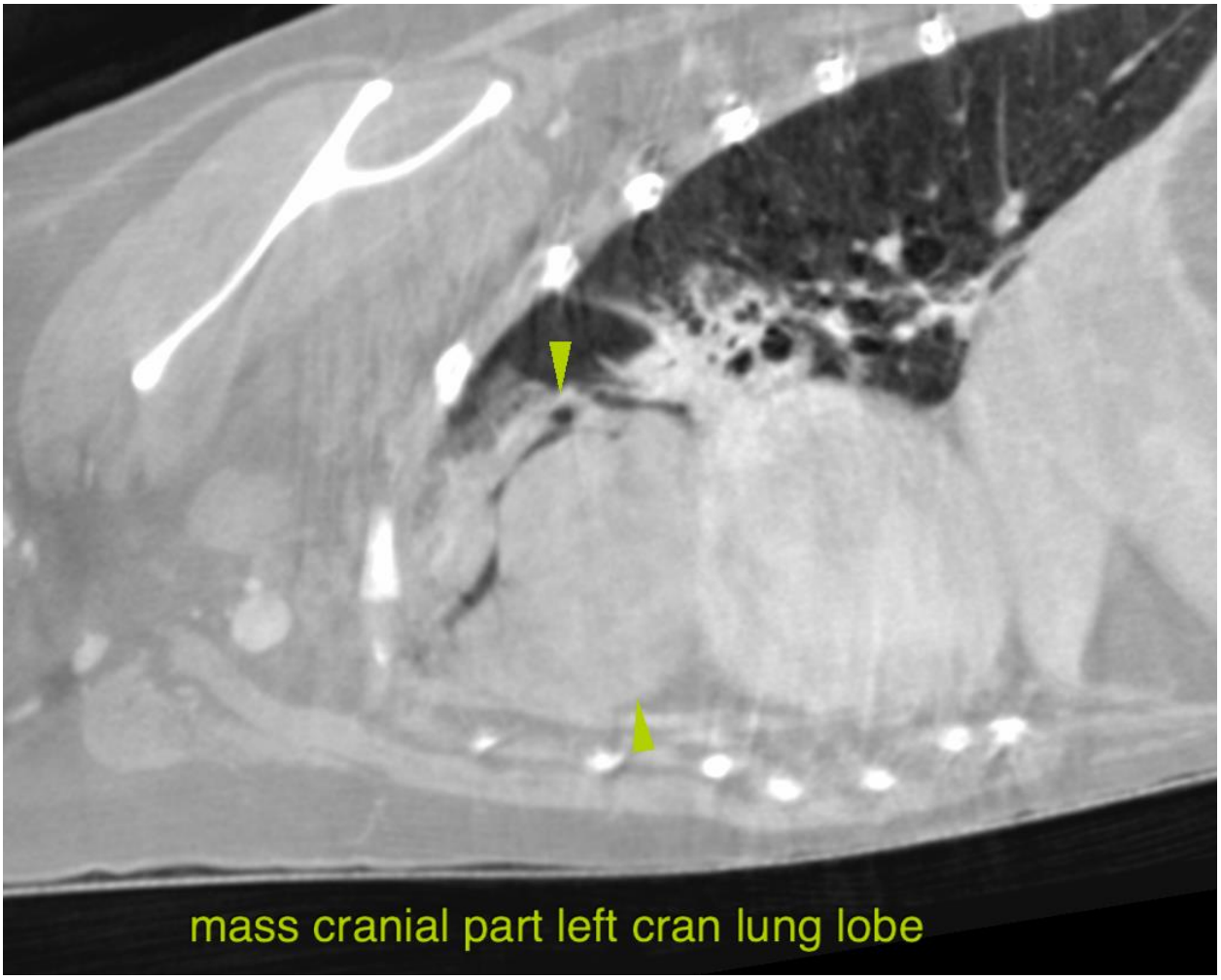

The information and recommendations provided are based on the images presented by the referring veterinarian. No evaluation can be communicated regarding pathology that was not visible in the image/video clips provided.

Thank you for this referral. If the clinical or image interpretation does not parallel your findings or if I can be of any further assistance please contact me.

Sebastian Schaub, Sebastian Schaub, DVM, Dr. med. vet. DipECVDI
sebast.schaub@gmail.com

SonoPath Teleradiology

EDUCATIONAL TELECONSULTATION SERVICES™

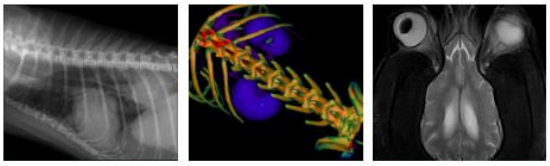

SonoPath.com

1-800-838-4268 info@sonopath.com

PATIENT

Elmo Law

SPECIES

Canine

BREED

Shih Tzu

SEX

Neutered Male

AGE

13 Years

INTERPRETED BY

Sebastian Schaub, DVM Dr. med. vet. DipECVDI

HOSPITAL NAME

Private Veterinary Specialties

REFERRING VET

Dr. Hamilton

INVOICE

14209

DATE

11/5/21