

**PATIENT**

Crystal Second
Chance Rescue

PRESENTING CLINICAL SIGNS

History of ear infections. Possible left ear mass.

COMPUTED TOMOGRAPHY OF THE SKULL**SPECIES**

Canine

A high resolution plain CT study of the skull is provided for review.

COMPUTED TOMOGRAPHIC FINDINGS

Triadan 207 is absent.

BREED

Labrador Retriever

The nasal cavity presents the expected aerated spaces between thin & even conchae and turbinates with smooth mucosal lining.

Both temporomandibular joints present congruent joint spaces with even subchondral bone surfaces and are considered within normal limits.

SEX

FS

A very mild amount of non-contrast enhancing soft tissue material is visible in the left tympanic bulla. The osseous lining of both tympanic bulla is thickened and mildly irregular. Both external ear canals present moderate to markedly shell like mineralization. The external ear canals present moderate mural thickening with an undulating epithelial lining.

AGE

9 Years

The brain presents no deviation from normal anatomy and symmetry. The brain parenchyma is homogeneous and within normal limits for attenuation. The ventricular system is non-dilated and symmetric.

INTERPRETED BY

Sebastian Schaub, DVM
Dr. med. vet. DipECVDI

The submandibular and medial retropharyngeal lymph nodes are small and elongated with a normal short-to-long-axis-ratio is < 0.5, the attenuation pattern is uniform.

COMPUTED TOMOGRAPHIC DIAGNOSIS

- Advanced chronic otitis externa with dystrophic mineralization of the external ear canals
- Evidence of chronic otitis media
- Absent triadan 207

HOSPITAL NAME

Animal Surgical
Center

INTERPRETATION OF THE FINDINGS & FURTHER RECOMMENDATIONS**REFERRING VET**

Rescue

The changes of the external ear canals are fitting the history of chronic otitis externa – possible hypertrophic – with significant thickening of the epithelial lining, R>L. Either conservative management of the otitis externa or surgical management (e.g. total ear canal ablation) are considerations here. There is no evidence of a mass.

INVOICE

48270

DATE

11-5-21



PATIENT

Crystal Second
Chance Rescue

SPECIES

Canine

BREED

Labrador Retriever

SEX

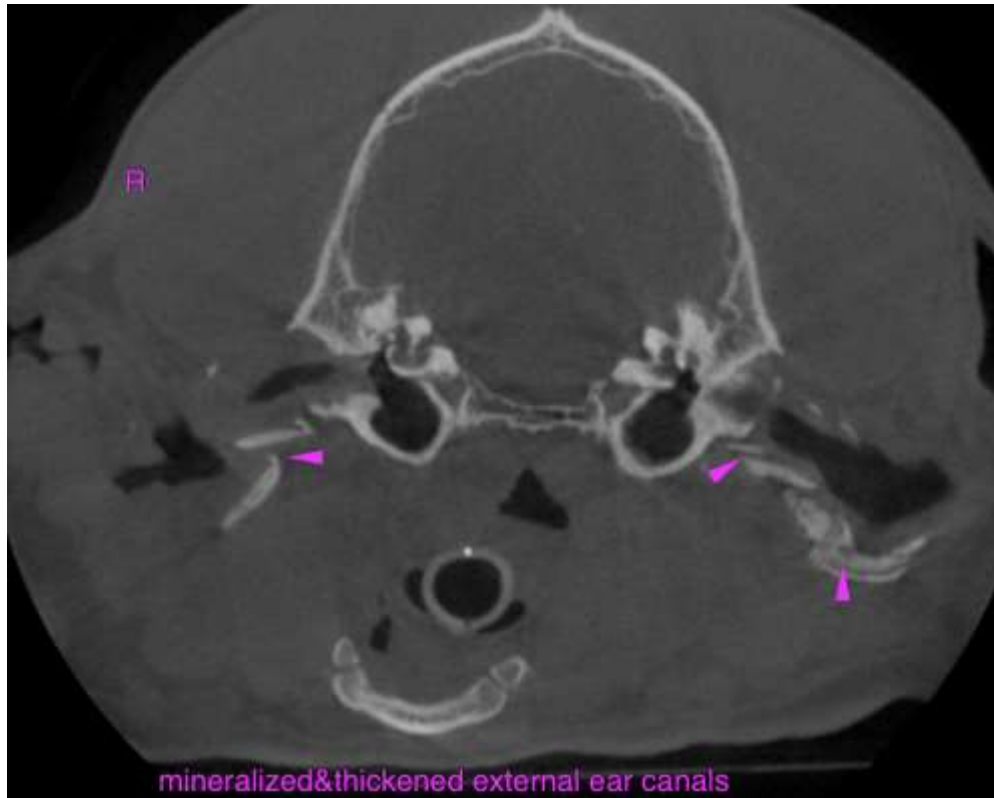
FS

AGE

9 Years

INTERPRETED BY

Sebastian Schaub, DVM
Dr. med. vet. DipECVDI



HOSPITAL NAME

Animal Surgical
Center

REFERRING VET

Rescue

INVOICE

48270

DATE

11-5-21

The information and recommendations provided are based on the images presented by the referring veterinarian. No evaluation can be communicated regarding pathology that was not visible in the image/video clips provided.

Thank you for this referral. If the clinical or image interpretation does not parallel your findings or if I can be of any further assistance please contact me.

Sebastian Schaub, Sebastian Schaub, DVM, Dr. med. vet. DipECVDI
sebast.schaub@gmail.com