



**PATIENT**

Mia Jordan

**PRESENTING CLINICAL SIGNS**

Chronic, severe sneezing

**COMPUTED TOMOGRAPHY OF THE SKULL**

**SPECIES**

Canine

A high resolution pre- and post-contrast CT study of the skull is provided for review.

**COMPUTED TOMOGRAPHIC FINDINGS**

Triadan 208 is absent.

**BREED**

Mixed

The nasal cavity presents the expected aerated spaces between thin & even conchae and turbinates with smooth mucosal lining.

Both temporomandibular joints present congruent joint spaces with even subchondral bone surfaces and are considered within normal limits.

**SEX**

FS

Both tympanic bullae are aerated, the mucosal lining is not seen, the bony wall is smooth and thin. The external ear canals are within normal limits.

The brain presents no deviation from normal anatomy and symmetry. The brain parenchyma is homogeneous and within normal limits for attenuation and distribution of contrast enhancement. The ventricular system is non-dilated and symmetric.

**AGE**

9 Years

The submandibular and medial retropharyngeal lymph nodes are small and elongated with a normal short-to-long-axis-ratio is  $< 0.5$ , the attenuation and contrast enhancement pattern is uniform.

**INTERPRETED BY**

Sebastian Schaub, DVM  
Dr. med. vet. DipECVDI

**COMPUTED TOMOGRAPHIC DIAGNOSIS**

- Structural normal upper airways
- Structural normal skull

**HOSPITAL NAME**

Animal Medical  
Center of Mt.  
Pleasant

**INTERPRETATION OF THE FINDINGS & FURTHER RECOMMENDATIONS**

The current CT study of the skull is negative for clinically relevant disease, the upper airways are aerated, and no abnormalities are appreciated. Complementing workup by rhinoscopy including biopsy to rule out non-specific rhinitis or nasal mites can be considered as an advanced diagnostic test.

**REFERRING VET**

Tess Lawhon, DVM

**INVOICE**

54999

**DATE**

11-4-22



**PATIENT**

Mia Jordan

**SPECIES**

Canine

**BREED**

Mixed

**SEX**

FS

**AGE**

9 Years

**INTERPRETED BY**

Sebastian Schaub, DVM  
Dr. med. vet. DipECVDI

**HOSPITAL NAME**

Animal Medical  
Center of Mt.  
Pleasant

**REFERRING VET**

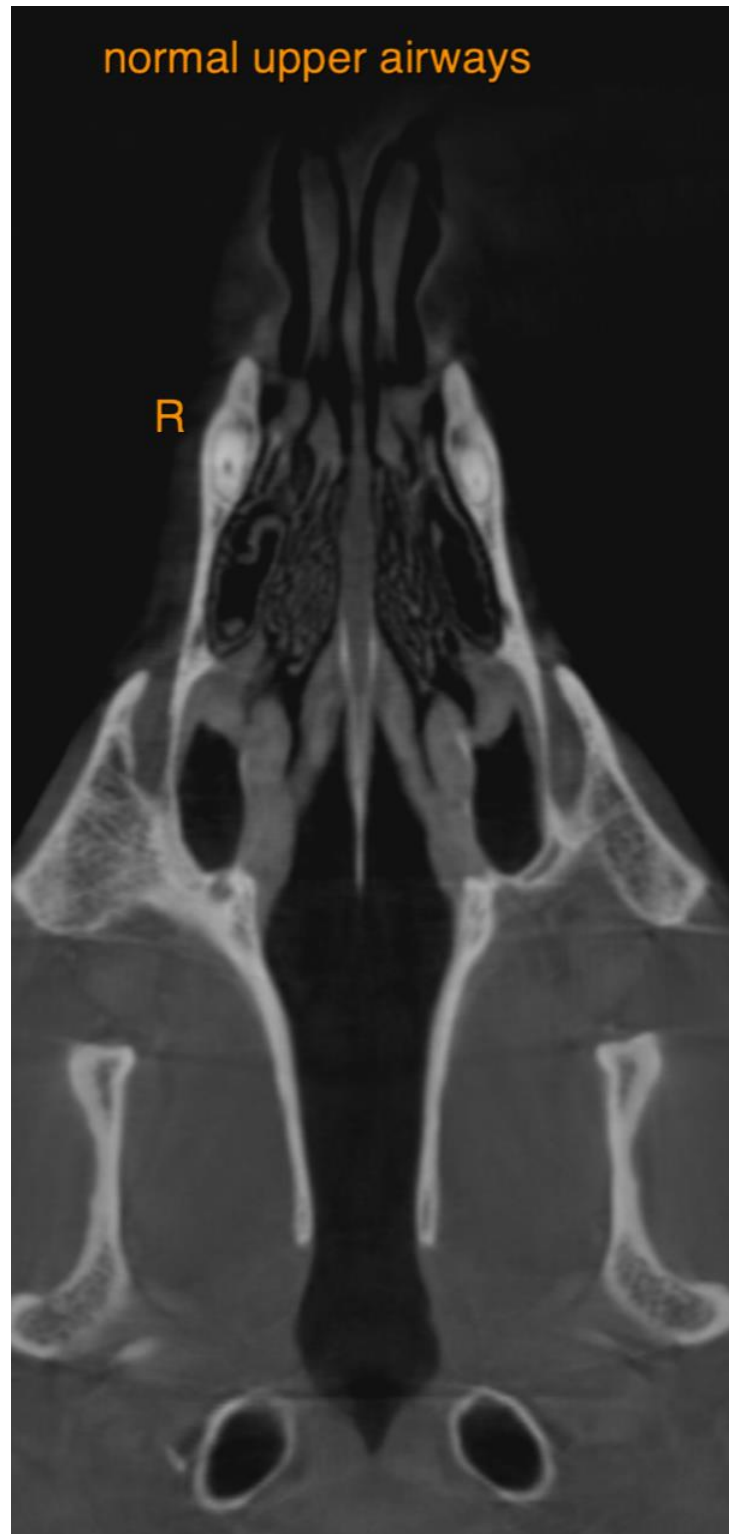
Tess Lawhon, DVM

**INVOICE**

54999

**DATE**

11-4-22





**PATIENT**

Mia Jordan

**SPECIES**

Canine

The information and recommendations provided are based on the images presented by the referring veterinarian/sonographer. No evaluation can be communicated regarding pathology that was not visible in the image/video clips provided.

**BREED**

Mixed

Thank you for this referral. If the clinical or image interpretation does not parallel your findings or if I can be of any further assistance please contact me.

**Sebastian Schaub**, Sebastian Schaub, DVM, Dr. med. vet. DipECVDI  
sebast.schaub@gmail.com

**SEX**

FS

**AGE**

9 Years

**INTERPRETED BY**

Sebastian Schaub, DVM  
Dr. med. vet. DipECVDI

**HOSPITAL NAME**

Animal Medical  
Center of Mt.  
Pleasant

**REFERRING VET**

Tess Lawhon, DVM

**INVOICE**

54999

**DATE**

11-4-22