



**PATIENT**

Basil Laico

**PRESENTING CLINICAL SIGNS**

heavy breathing for couple of days and sometimes gasp for air doing well otherwise  
Abnormal PE/Chem/CBC/UA Results: none

**SPECIES**

Feline

**RADIOGRAPHIC STUDY OF THE THORAX**

Radiographs of the thorax in three imaging planes are provided for review.

**BREED**

DSH

The surrounding bony structures are within normal limits.

The extrathoracic soft tissues present homogeneous without abnormalities.

**SEX**

FS

The heart is of normal size and shape, there is no evidence of cardiac chamber or vascular enlargement. The pulmonary vasculature is within normal limits.

The trachea is normal in diameter and presents the anticipated course. The luminal outline of the trachea is smooth.

**AGE**

3 Years

The left cranial and the left caudal lung lobe are consolidated and present a significantly decreased volume. A midline shift of the heart to the left is seen. The right lung lobes are hyperinflated. The right lung lobes present a mild increased visibility of the bronchial walls.

The left crus of the diaphragm is in a mild cranial position relative to the right crus.

**INTERPRETED BY**

Sebastian Schaub, DVM  
Dr. med. vet. DipECVDI

**RADIOGRAPHIC DIAGNOSIS**

- Consolidation of the left lung lobes with significantly decreased volume
- Hyperinflation right lung lobes
- Mild bronchial pattern right lung lobes

**HOSPITAL NAME**

Samuel Gabriel

**INTERPRETATION OF THE FINDINGS & FURTHER RECOMMENDATIONS**

The radiographic changes are highly suggestive for underlying feline bronchial disease ('feline asthma') with hyperinflation of the right lung lobes and likely resorption atelectasis of the left lung lobes – possibly due to mucus plugging of the left main bronchi or preceding chronic bronchopneumonia. Other potentials such as a peribronchial mass compressing the left principal bronchus or aspirated foreign body obliterating the left principal bronchus are considered far less likely.

**REFERRING VET**

Gabriel

**INVOICE**

54955

**DATE**

11-4-22



**PATIENT**

Basil Laico

**SPECIES**

Feline

**BREED**

DSH

**SEX**

FS

**AGE**

3 Years

**INTERPRETED BY**

Sebastian Schaub, DVM  
Dr. med. vet. DipECVDI

**HOSPITAL NAME**

Samuel Gabriel

**REFERRING VET**

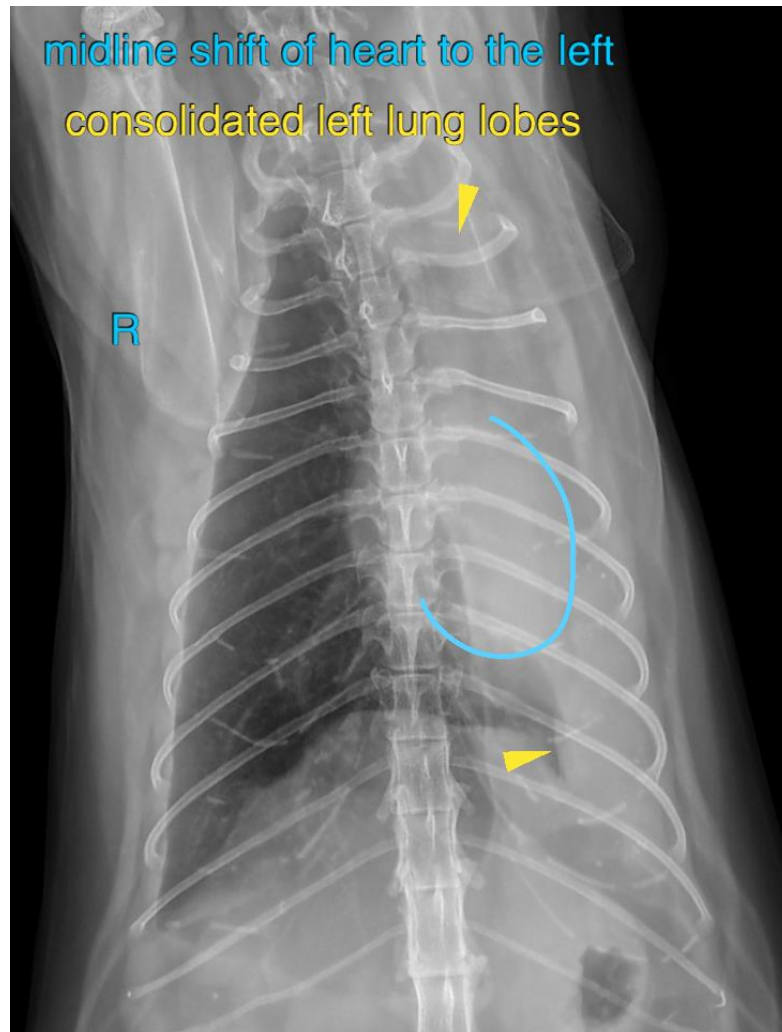
Gabriel

**INVOICE**

54955

**DATE**

11-4-22



The information and recommendations provided are based on the images presented by the referring veterinarian/sonographer. No evaluation can be communicated regarding pathology that was not visible in the image/video clips provided.

Thank you for this referral. If the clinical or image interpretation does not parallel your findings or if I can be of any further assistance please contact me.

**Sebastian Schaub**, Sebastian Schaub, DVM, Dr. med. vet. DipECVDI  
sebast.schaub@gmail.com