SonoPath Teleradiology

EDUCATIONAL TELECONSULTATION SERVICES™

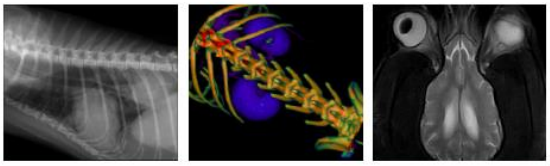

SonoPath.com
1-800-838-4268 info@sonopath.com

PATIENT

Meredith Beckman

SPECIES

Canine

BREED

Maltese Mix

SEX

Spayed Female

AGE

1.3 Years

INTERPRETED BY

Sebastian Schaub, DVM Dr. med. vet. DipECVDI

HOSPITAL NAME

Boca Park AH

REFERRING VET

Laura Warren

INVOICE

14204

DATE

11/4/21

PRESENTING CLINICAL SIGNS

History: Acute RF lameness and crying in pain at home, no pain elicited upon examination
Abnormal PE/Chem/CBC/UA Results:

RADIOGRAPHIC STUDY OF THE FRONT LIMB

Radiographs of the right elbow and carpal joint are provided for review.

RADIOGRAPHIC FINDINGS

The osseous structures of right elbow are within normal limits.

Cranial to the proximal segment of the right radius, a mild subcutaneous soft tissue swelling is visible.

The osseous and soft tissue structures of the carpal joint are within normal limits.

RADIOGRAPHIC DIAGNOSIS

- Suspect subcutaneous soft tissue swelling cranioproximal aspect right antebrachium

INTERPRETATION OF THE FINDINGS & FURTHER RECOMMENDATIONS

There is a subjective subcutaneous swelling at the cranial aspect of the proximal aspect of the antebrachium, top differentials include trauma ± hematoma formation or steatitis (e.g., insect bite, bite wound?). Check if swelling can be appreciated clinically. The osseous structures present without abnormalities.

SonoPath Teleradiology

EDUCATIONAL TELECONSULTATION SERVICES™

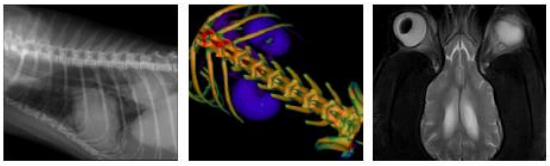

SonoPath.com
1-800-838-4268 info@sonopath.com

PATIENT

Meredith Beckman

SPECIES

Canine

BREED

Maltese Mix

SEX

Spayed Female

AGE

1.3 Years

INTERPRETED BY

Sebastian Schaub, DVM Dr. med. vet. DipECVDI

HOSPITAL NAME

Boca Park AH

REFERRING VET

Laura Warren

INVOICE

14204

DATE

11/4/21

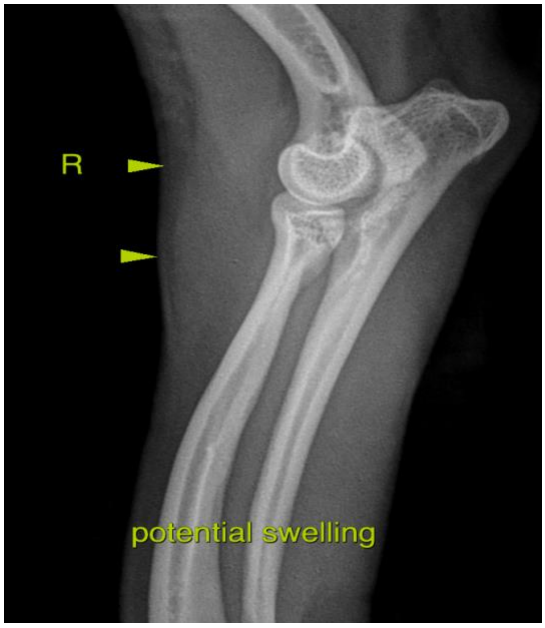

The information and recommendations provided are based on the images presented by the referring veterinarian. No evaluation can be communicated regarding pathology that was not visible in the image/video clips provided.

Thank you for this referral. If the clinical or image interpretation does not parallel your findings or if I can be of any further assistance please contact me.

Sebastian Schaub, Sebastian Schaub, DVM, Dr. med. vet. DipECVDI
sebast.schaub@gmail.com