



PATIENT PRESENTING CLINICAL SIGNS

Penny Meza
 Penny is owned by one of our veterinary technicians, who noticed she was limping on her left hind for the last month
 Abnormal PE/Chem/CBC/UA Results: blood work pending PE: luxating patella grade 3 left hind and positive drawer motion

SPECIES

Feline

RADIOGRAPHIC STUDY OF THE STIFLE JOINTS

Radiographs of both stifle joints in two orthogonal imaging planes are provided for review.

BREED

DSH

RADIOGRAPHIC FINDINGS

The volume of the soft tissue shadow of the left thigh musculature is mildly decreased.

SEX

FS

Both stifle joints present smooth osseous margins. The growth plate of the apophysis of the tibia is still open. The left stifle joint presents a significant intracapsular soft tissue swelling, effacing the infrapatellar fat pad cranially. The right stifle joint presents without evidence of intracapsular swelling. The patella of the left stifle joint is located medial to the medial femoral condyle in the craniocaudal projection.

RADIOGRAPHIC DIAGNOSIS

AGE

1.5 Years

- Left sided medial patellar luxation
- Moderate articular swelling left stifle joint
- Disuse atrophy left thigh musculature
- Normal right stifle joint

INTERPRETED BY

Sebastian Schaub, DVM
 Dr. med. vet. DipECVDI

INTERPRETATION OF THE FINDINGS & FURTHER RECOMMENDATIONS

The radiographic study is consistent with the clinically appreciated left sided medial patellar luxation. The joint effusion might be a sequela to the patellar luxation, however given the results of the clinical examination there is suspicion for failure of the cranial cruciate ligament and traumatic origin of the patellar luxation needs to be considered.

If blood work reveals signs for inflammation, recommend complementing workup by a synovial tap to rule out infectious arthritis.

HOSPITAL NAME

Northshore
 Veterinary Hospital

REFERRING VET

Brita Kiffney

INVOICE

55473

DATE

11-30-22



PATIENT

Penny Meza

SPECIES

Feline

BREED

DSH

SEX

FS

AGE

1.5 Years

INTERPRETED BY

Sebastian Schaub, DVM
Dr. med. vet. DipECVDI

HOSPITAL NAME

Northshore
Veterinary Hospital

REFERRING VET

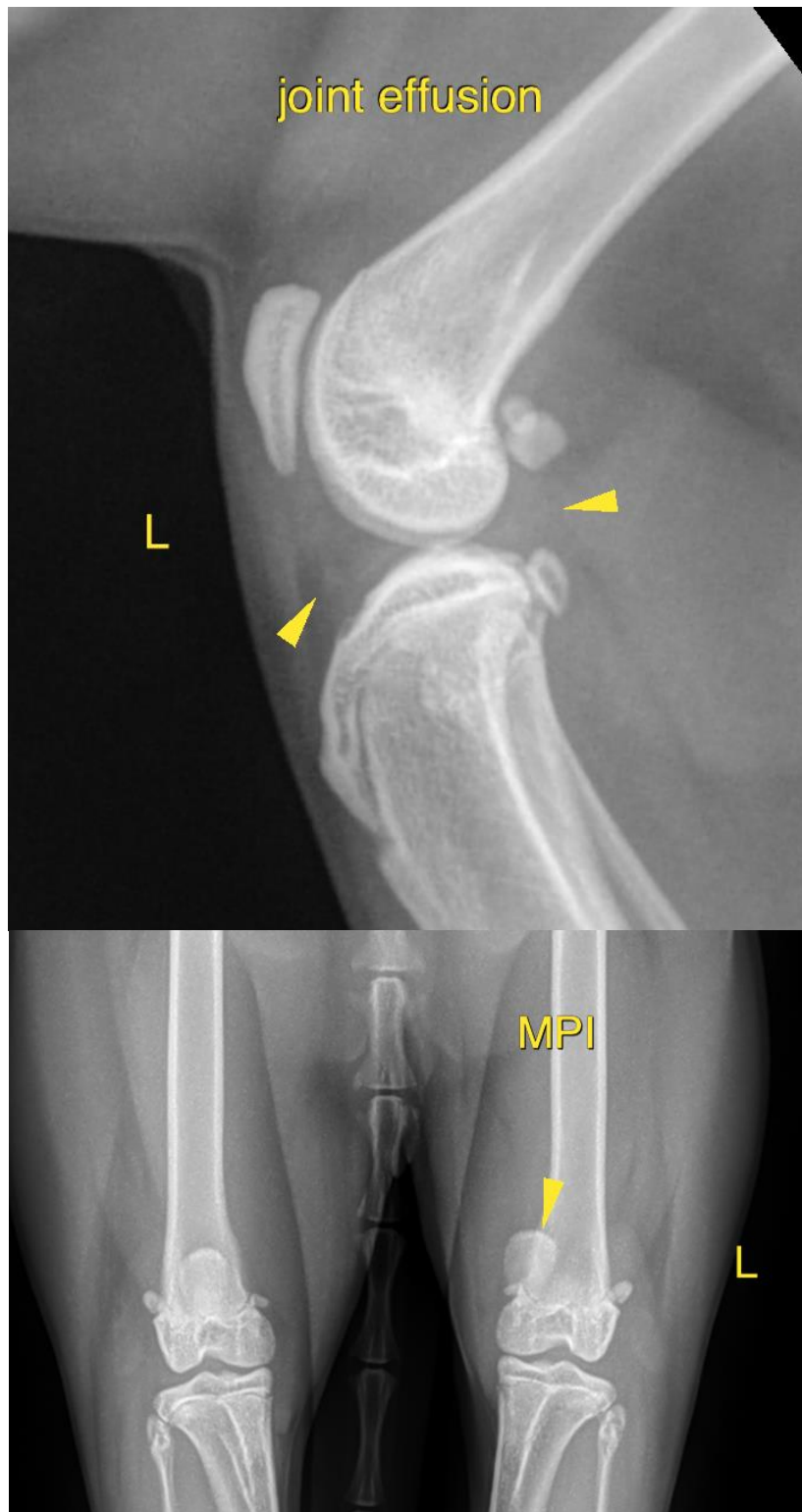
Brita Kiffney

INVOICE

55473

DATE

11-30-22





PATIENT

Penny Meza

The information and recommendations provided are based on the images presented by the referring veterinarian/sonographer. No evaluation can be communicated regarding pathology that was not visible in the image/video clips provided.

SPECIES

Feline

Thank you for this referral. If the clinical or image interpretation does not parallel your findings or if I can be of any further assistance please contact me.

BREED

DSH

Sebastian Schaub, Sebastian Schaub, DVM, Dr. med. vet. DipECVDI
sebast.schaub@gmail.com

SEX

FS

AGE

1.5 Years

INTERPRETED BY

Sebastian Schaub, DVM
Dr. med. vet. DipECVDI

HOSPITAL NAME

Northshore
Veterinary Hospital

REFERRING VET

Brita Kiffney

INVOICE

55473

DATE

11-30-22