



**PATIENT**

Kennedy Doyle

**PRESENTING CLINICAL SIGNS**

O unsure of what happened today. P was at groomers and started yelping and holding up left hind. Hx of lameness on left hind.

Abnormal PE/Chem/CBC/UA Results: painful on flexion of left stifle and noted luxating patella. intermittent lameness on left hind but able to stand on hind legs.

**SPECIES**

Canine

**RADIOGRAPHIC STUDY OF THE STIFLE JOINTS**

Radiographs of both stifle joints in two orthogonal imaging planes are provided for review.

**BREED**

Bichon

**RADIOGRAPHIC FINDINGS**

The volume of the soft tissue shadow of the right thigh musculature is mildly decreased.

The periarticular bones of both stifle joints present moderate osteophyte new bone formation. Bilateral osseous elongation of the tibial plateau is appreciated. The tibia bilaterally is subluxated cranially, R>L. The right stifle joint presents evidence of mild intracapsular soft tissue swelling. The left stifle joint presents without evidence of intracapsular swelling. In the craniocaudal projection, the patella of the left stifle joint is superimposed on the medial femoral condyle.

**SEX**

Male (Neutered)

**RADIOGRAPHIC DIAGNOSIS**

**AGE**

9 Years

- Degenerative osteoarthritis stifle joints bilaterally and caudal osseous elongation of the tibial plateau
- Cranial tibial subluxation, R>>L
- Articular swelling right stifle joint
- Left sided medial patellar luxation – likely incidental due to the age of the patient
- Disuse atrophy right thigh musculature

**INTERPRETED BY**

Sebastian Schaub, DVM  
Dr. med. vet. DipECVDI

**INTERPRETATION OF THE FINDINGS & FURTHER RECOMMENDATIONS**

**HOSPITAL NAME**

The Pet Hospital of  
Stratford

The radiographic study is consistent with bilateral chronic degenerative osteoarthritis with joint effusion of the right stifle joint due to failure of the cranial cruciate ligament ± meniscal disease.

A positive drawer sign or tibial compression test under general anesthesia can be used to confirm the diagnosis.

**REFERRING VET**

Dr. Claudia Giuliani

**INVOICE**

55472

**DATE**

11-30-22



**PATIENT**

Kennedy Doyle

**SPECIES**

Canine

**BREED**

Bichon

**SEX**

Male (Neutered)

**AGE**

9 Years

**INTERPRETED BY**

Sebastian Schaub, DVM  
Dr. med. vet. DipECVDI

**HOSPITAL NAME**

The Pet Hospital of  
Stratford

**REFERRING VET**

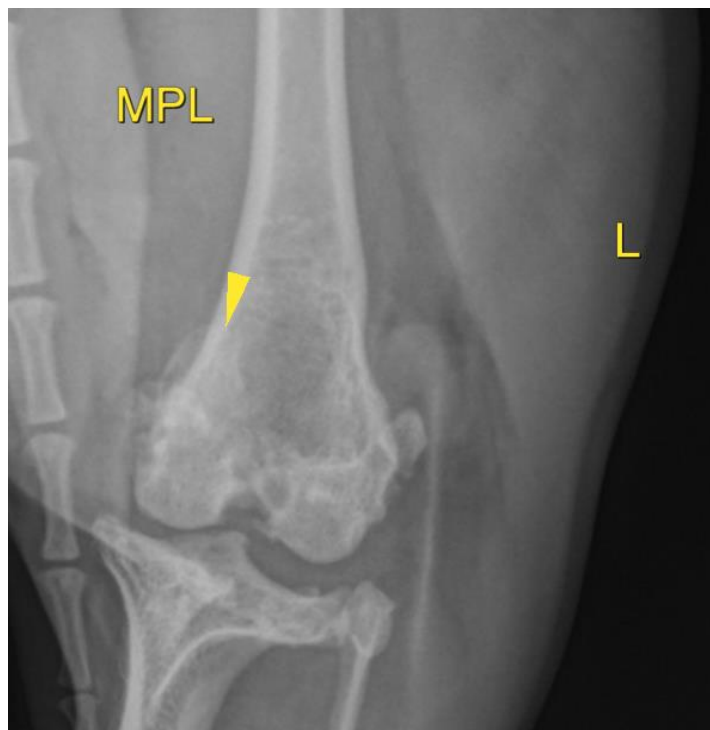
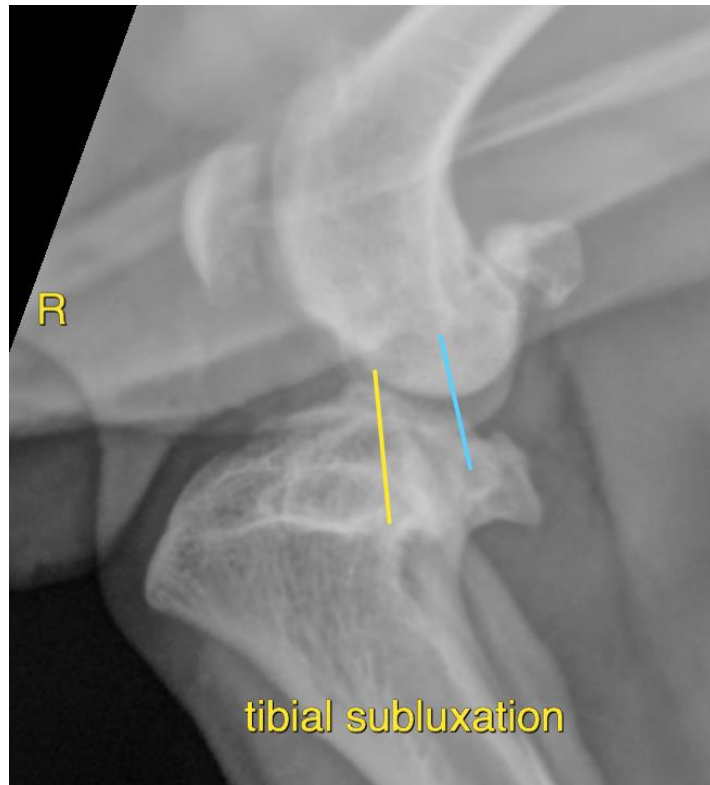
Dr. Claudia Giuliani

**INVOICE**

55472

**DATE**

11-30-22





**PATIENT**

Kennedy Doyle

**SPECIES**

Canine

**BREED**

Bichon

**SEX**

Male (Neutered)

**AGE**

9 Years

**INTERPRETED BY**

Sebastian Schaub, DVM  
Dr. med. vet. DipECVDI

**HOSPITAL NAME**

The Pet Hospital of  
Stratford

**REFERRING VET**

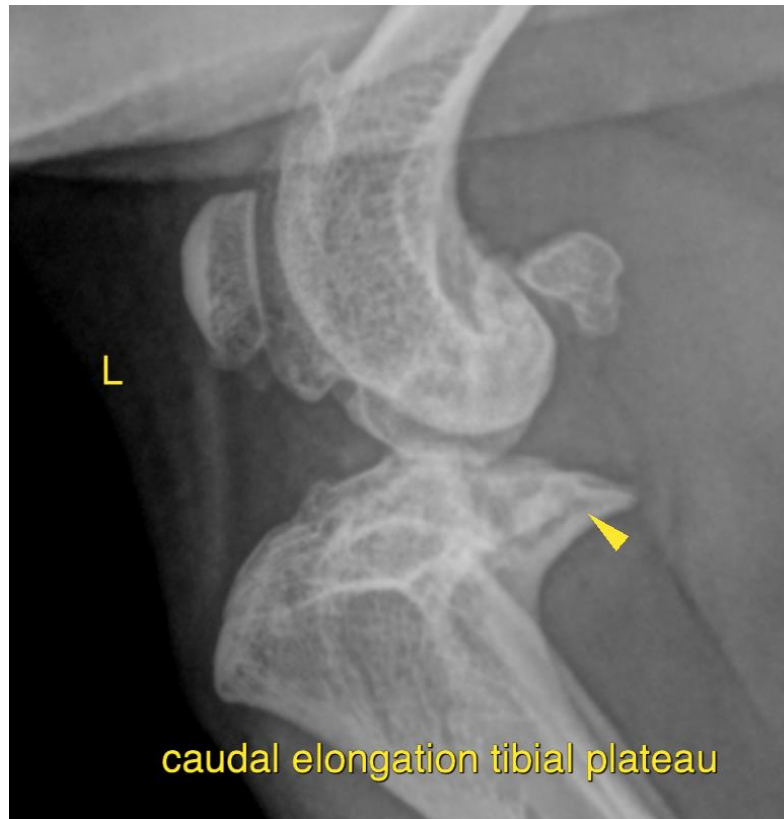
Dr. Claudia Giuliani

**INVOICE**

55472

**DATE**

11-30-22



The information and recommendations provided are based on the images presented by the referring veterinarian/sonographer. No evaluation can be communicated regarding pathology that was not visible in the image/video clips provided.

Thank you for this referral. If the clinical or image interpretation does not parallel your findings or if I can be of any further assistance please contact me.

**Sebastian Schaub**, Sebastian Schaub, DVM, Dr. med. vet. DipECVDI  
sebast.schaub@gmail.com