



PATIENT PRESENTING CLINICAL SIGNS

PATIENT Axel Struchen
 dragging front left shoulder for about a month
 Abnormal PE/Chem/CBC/UA Results: Eyes: bright and clear, mild third eyelid elevation Ears: clean with no inflammation Nose and throat: no abnormality Heart: No noted arrhythmia or pulse deficits, normal subjective peripheral circulation Lungs: normal respiratory sounds, rate and effort Abdomen: soft and non-painful with no noted abnormalities Musculoskeletal: No significant musculoskeletal abnormalities Integument: Clean and smooth hair coat Lymph Nodes: Normal size and firmness Neurological: Abnormal: Cranial nerves appear normal but third eyelid elevation is present but may be breed associated. Ambulation shows moderate ataxia in all limbs. More significant on left side. The myotatic reflexes are normal to mildly increased. CP delays are noted in both hind limbs.

SPECIES Canine

BREED Coonhound

MAGNETIC RESONANCE IMAGING OF THE CERVICAL SPINE

T2&T1 weighted pre- and post-gadolinium sequences in multiple imaging planes are provided for review.

SEX

MN

MAGNETIC RESONANCE IMAGING FINDINGS

Moderate hypertrophy of the facet joints C3/C4, C4/C5 and C6/C7 is appreciated, narrowing the vertebral canal at the same level – approximately 50% decreased cross-sectional area of the vertebral canal. The spinal cord level C3/C4 to C6/C7 is distorted. The central canal level C3 is mildly dilated.

AGE

4 Years

Mild stenosis of the vertebral canal level C7/T1 is appreciated.

INTERPRETED BY

Sebastian Schaub, DVM
 Dr. med. vet. DipECVDI

MAGNETIC RESONANCE IMAGING DIAGNOSIS

- Cervical spondylomyelopathy C3/C4 to C6/C7 due to hyperostosis of the respective facet joints

INTERPRETATION OF THE FINDINGS & FURTHER RECOMMENDATIONS

The cervical spondylomyelopathy secondary to hyperostosis multiple facet joints along the cervical spine is a plausible explanation for the presenting clinical signs. Recommend discussing potential palliative treatment options with neurologist.

HOSPITAL NAME

Mountain West
 Veterinary Hospital

REFERRING VET

Burton

INVOICE

55463

DATE

11-30-22



PATIENT

Axel Struchen

SPECIES

Canine

BREED

Coonhound

SEX

MN

AGE

4 Years

INTERPRETED BY

Sebastian Schaub, DVM
Dr. med. vet. DipECVDI

HOSPITAL NAME

Mountain West
Veterinary Hospital

REFERRING VET

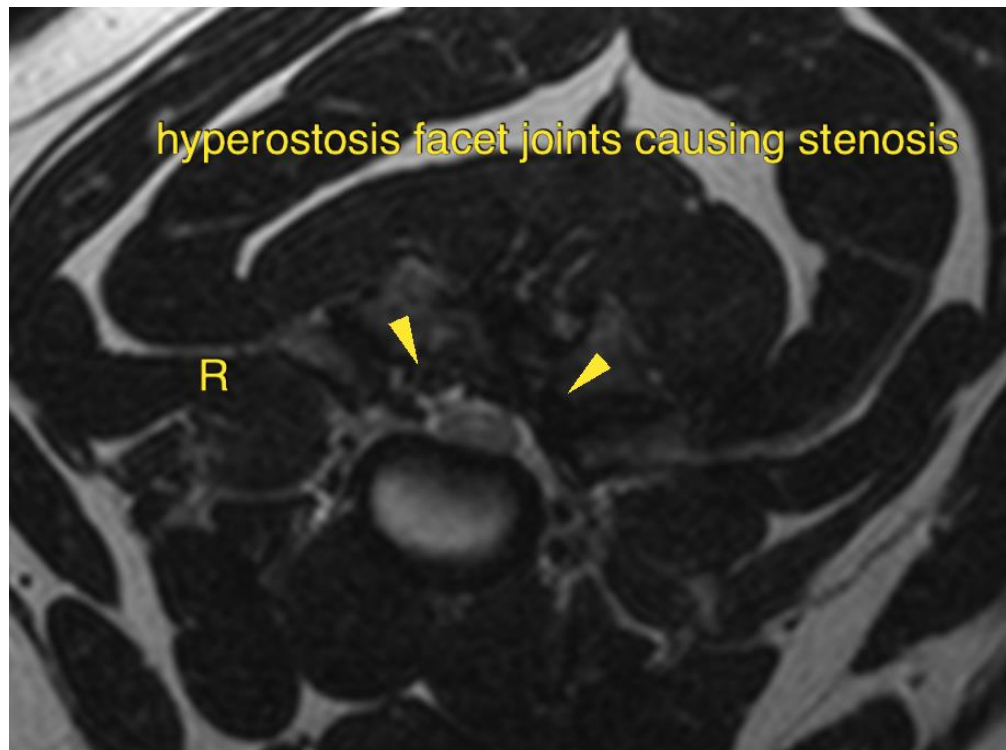
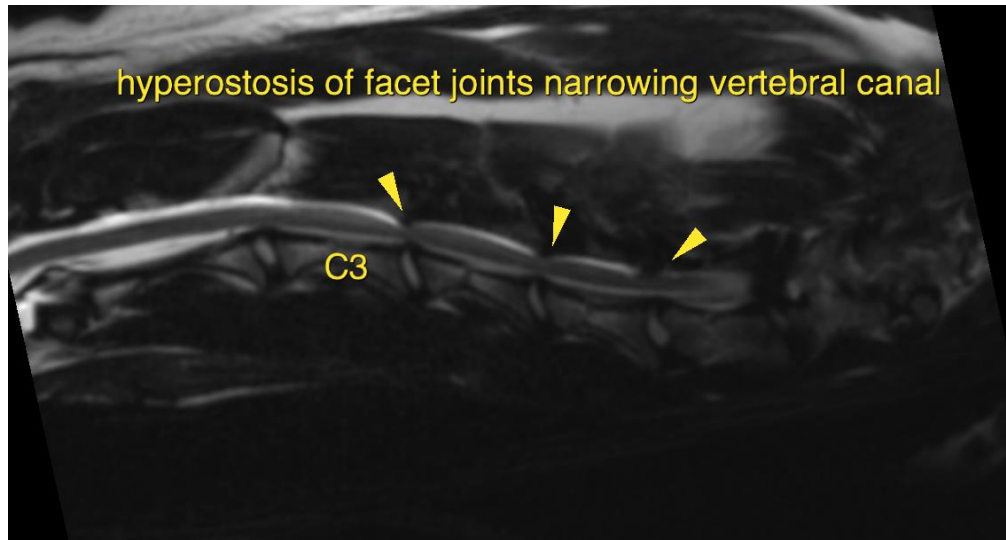
Burton

INVOICE

55463

DATE

11-30-22





PATIENT

Axel Struchen

SPECIES

Canine

BREED

Coonhound

SEX

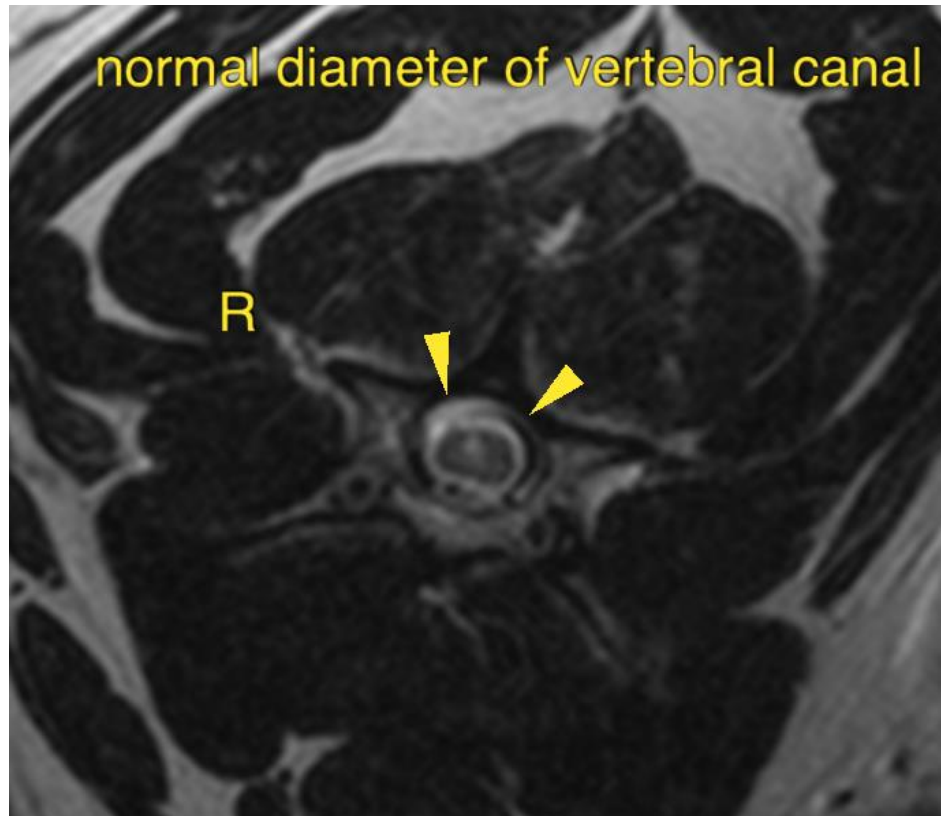
MN

AGE

4 Years

INTERPRETED BY

Sebastian Schaub, DVM
Dr. med. vet. DipECVDI



HOSPITAL NAME

Mountain West
Veterinary Hospital

REFERRING VET

Burton

INVOICE

55463

DATE

11-30-22

The information and recommendations provided are based on the images presented by the referring veterinarian/sonographer. No evaluation can be communicated regarding pathology that was not visible in the image/video clips provided.

Thank you for this referral. If the clinical or image interpretation does not parallel your findings or if I can be of any further assistance please contact me.

Sebastian Schaub, Sebastian Schaub, DVM, Dr. med. vet. DipECVDI
sebast.schaub@gmail.com