



**PATIENT**

Piper Chapkin

**PRESENTING CLINICAL SIGNS**

Concern is liver mass recurrence/metastasis in other lobes? - Hx splenectomy - Liver lobectomy - Cutaneous HSA, Stable on propranol - Hx melanoma - Hx stroke, seizures, stable

**SPECIES**

Canine

**COMPUTED TOMOGRAPHY OF THE THORAX AND ABDOMEN**

A high resolution pre- and post-contrast CT study of the abdomen and a post-contrast CT study of the thorax are provided for review.

**BREED**

Wheaten Terrier

**COMPUTED TOMOGRAPHIC FINDINGS**

Thorax

The vertebral endplates T2/T3 present mild spondylosis formation.

**SEX**

Female Spayed

The sternal, cranial mediastinal and tracheobronchial lymph nodes are small elongated with a normal short-to-long-axis-ratio is < 0.5, the attenuation and contrast enhancement pattern is uniform and considered within normal limits.

**AGE**

14 Years

The cardiovascular structures including the pulmonary vasculature are within normal limits.

The bronchial tree presents with regular branching and tapers uniformly towards the periphery as expected, the bronchial walls are thin and smooth. The bronchus-to-artery ratio is within normal limits.

**INTERPRETED BY**

Sebastian Schaub, DVM  
Dr. med. vet. DipECVDI

The lung parenchyma presents the expected architecture and attenuation behavior with interspersed punctuate mineralization.

Small incidental gas pockets are seen within the esophageal lumen, there is no evidence of abnormal dilation.

**HOSPITAL NAME**

Mobile Pet Imaging

Abdomen

The serosal fat presents normal attenuation behavior. There is no evidence of peritoneal effusion or peritonitis.

**REFERRING VET**

Meaux

Both kidneys present within normal limits for size, shape and organ architecture. After contrast administration a bilaterally symmetric and uniform nephro- and pyelogram is noted.

**INVOICE**

48664

The adrenal glands are within normal limits for size, shape and organ architecture.

The hepatic volume is moderately increased and the caudoventral margins are rounded, parts of the left aspect of the liver are absent. The margins of the caudate process of the caudate liver lobe are overall rounded. The hepatic parenchyma is uniform soft tissue attenuating and the contrast enhancement pattern is mildly heterogeneous.

**DATE**

11-30-21

The spleen is absent.

The pancreas is evenly contoured, the pancreatic parenchyma is homogeneous and presents uniform contrast enhancement.



**PATIENT**

Piper Chapkin

The position, delineation, wall and content of the gastrointestinal tract are considered within normal limits throughout.

**SPECIES**

Canine

The lumbosacral intervertebral disc is mildly protruding into the vertebral canal, mildly distorting the ventral epidural space at the same level.

**BREED**

Wheaten Terrier

**COMPUTED TOMOGRAPHIC DIAGNOSIS**

- Hepatomegaly, most accentuated the caudate process of the caudate liver lobe
- History of splenectomy
- Mild intervertebral disc protrusion L7/S1 without compressive myelopathy
- Mild spondylosis formation T2/T3
- Pulmonary osteomas
- No evidence of pulmonary metastatic disease
- No evidence of portosystemic shunting.

**SEX**

Female Spayed

**INTERPRETATION OF THE FINDINGS & FURTHER RECOMMENDATIONS**

**AGE**

14 Years

The is diffuse enlargement of the caudate process of the caudate liver lobe, no distinct mass is appreciated, and potentials include metabolic hepatic disease/hepatitis ± regeneration nodule formation or diffuse neoplastic invasion. Recommend ultrasound guided FNA sampling for further definition.

**INTERPRETED BY**

Sebastian Schaub, DVM  
Dr. med. vet. DipECVDI

No additional clinically relevant abnormalities are appreciated.

**HOSPITAL NAME**

Mobile Pet Imaging

**REFERRING VET**

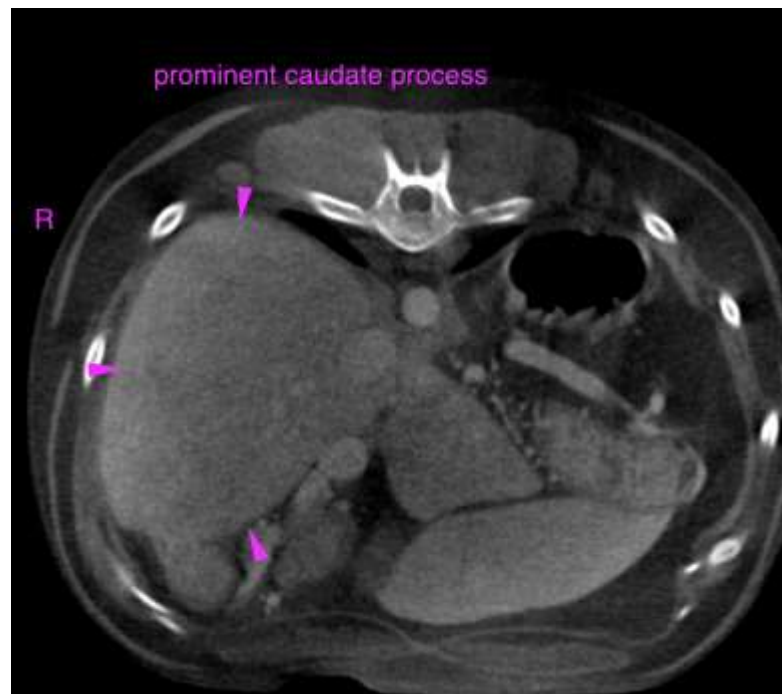
Meaux

**INVOICE**

48664

**DATE**

11-30-21





**PATIENT**

Piper Chapkin

The information and recommendations provided are based on the images presented by the referring veterinarian. No evaluation can be communicated regarding pathology that was not visible in the image/video clips provided.

Thank you for this referral. If the clinical or image interpretation does not parallel your findings or if I can be of any further assistance please contact me.

**SPECIES**

Canine

**Sebastian Schaub**, Sebastian Schaub, DVM, Dr. med. vet. DipECVDI  
sebast.schaub@gmail.com

**BREED**

Wheaten Terrier

**SEX**

Female Spayed

**AGE**

14 Years

**INTERPRETED BY**

Sebastian Schaub, DVM  
Dr. med. vet. DipECVDI

**HOSPITAL NAME**

Mobile Pet Imaging

**REFERRING VET**

Meaux

**INVOICE**

48664

**DATE**

11-30-21