



PATIENT

Bandit McNulty

SPECIES

Canine

BREED

Golden Retriever

SEX

Male Neutered

AGE

9 Years

INTERPRETED BY

Sebastian Schaub, DVM
Dr. med. vet. DipECVDI

HOSPITAL NAME

Mobile Pet Imaging

REFERRING VET

Meaux

INVOICE

48661

DATE

11-30-21

PRESENTING CLINICAL SIGNS

Presented to dentist with a Hx of Oral Mass 1.5 x 1.5 x 0.75 cm ulcerated oval pink pale palatal mass 5 - 10mm from the distopalatal line angle of the right mandibular first molar (109) with right caudal maxillary buccal bone and right rostral zygomatic bone expansion. Right caudal maxilla region was previously biopsied (10-12-21) revealing: Oral sarcoma consistent with a Spindle cell malignancy, differential Dx, soft tissue sarcoma, fibrosarcoma, peripheral nerve sheath tumor, or spindle amelanotic melanoma. Clinical staging has been performed by Animal Cancer Care Clinics. Treatment: Recommendation: Advanced imaging (CT Scan) to determine extent of neoplastic margins to create the most effective treatment plan to extend Bandits quality of life.

COMPUTED TOMOGRAPHY OF THE SKULL

A high resolution pre- and post-contrast CT study of the skull is provided for review.

COMPUTED TOMOGRAPHIC FINDINGS

The tooth element 110 is absent. Centered on the alveolar bone level with absent 110, a cauliflower like, expansile, mineralizing mass is visible, replacing the alveolar bone at the same level; the surrounding bone presents moderate sclerosis. The mineralizing mass is protruding laterally beyond the alveolar bone. The mineralizing mass is measuring 3.8 x 1.8 x 2.1 cm in size. In the medial aspect, there is osseous remodeling of the rostral segment of the right hamulus of the pterygoid bone.

The nasal cavity presents the expected aerated spaces between thin & even conchae and turbinates with smooth mucosal lining.

Both temporomandibular joints present congruent joint spaces with even subchondral bone surfaces and are considered within normal limits.

Both tympanic bullae are aerated, the mucosal lining is not seen, the bony wall is smooth and thin. The external ear canals are within normal limits.

The brain presents no deviation from normal anatomy and symmetry. The brain parenchyma is homogeneous and within normal limits for attenuation and distribution of contrast enhancement. The ventricular system is non-dilated and symmetric.

The submandibular and medial retropharyngeal lymph nodes are small and elongated with a normal short-to-long-axis-ratio is < 0.5, the attenuation and contrast enhancement pattern is uniform.

COMPUTED TOMOGRAPHIC DIAGNOSIS

- Polyostotic semi-aggressive osteoproliferative lesion alveolar process right maxillary bone, level 110
- Absent triadan 110



PATIENT

Bandit McNulty

SPECIES

Canine

BREED

Golden Retriever

SEX

Male Neutered

AGE

9 Years

INTERPRETED BY

Sebastian Schaub, DVM
Dr. med. vet. DipECVDI

HOSPITAL NAME

Mobile Pet Imaging

REFERRING VET

Meaux

INVOICE

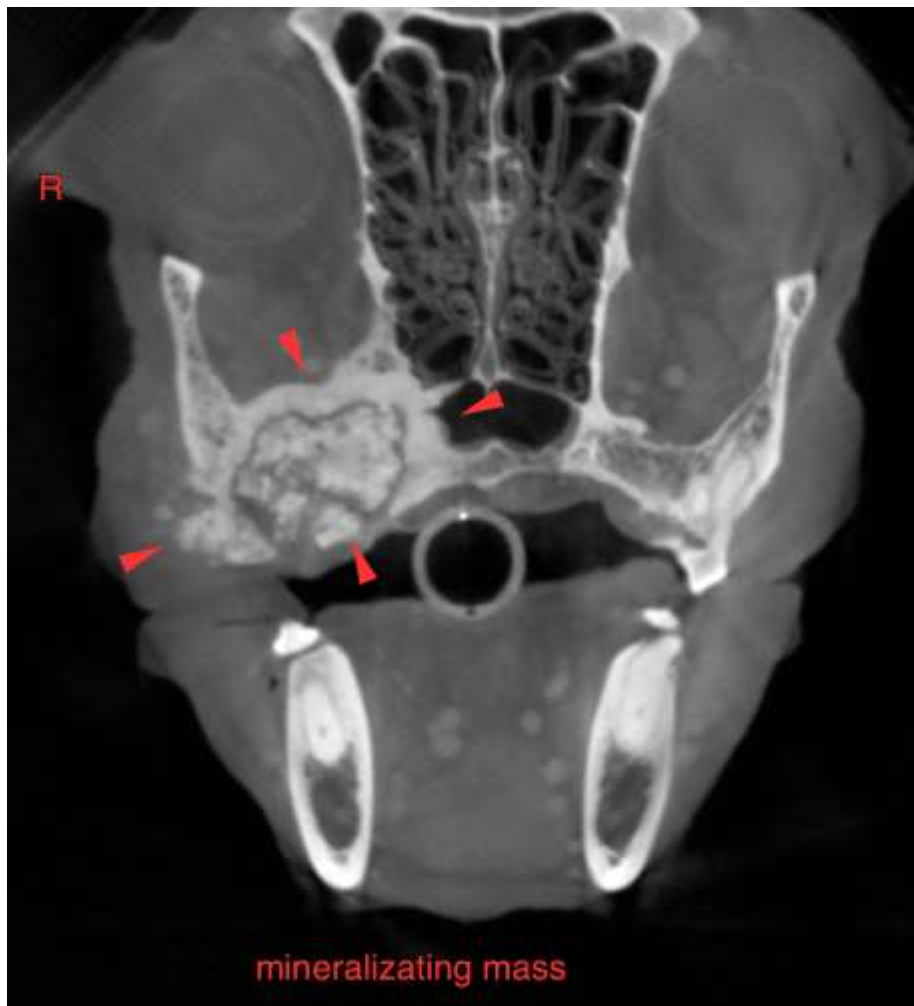48661

DATE

11-30-21

INTERPRETATION OF THE FINDINGS & FURTHER RECOMMENDATIONS

The mineralizing mass is consistent with the history of sarcoma formation. Complete surgical excision of the mass will warrant caudal hemimaxillectomy with osteotomy lines including the rostral segment of the right hamulus, caudal margin of the horizontal plate of the right palatine bone and mesial to triadan 108. Resection of the rostral segment of the right zygomatic arch would be necessary as well.





PATIENT

Bandit McNulty

SPECIES

Canine

BREED

Golden Retriever

SEX

Male Neutered

AGE

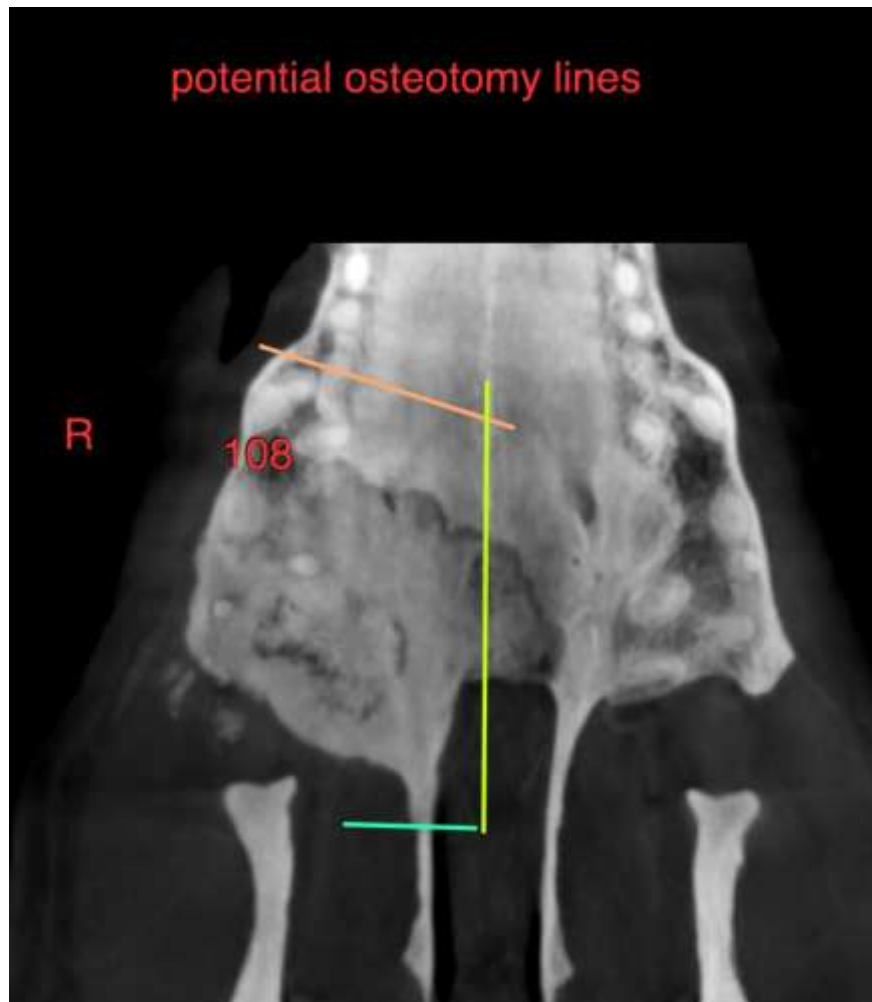
9 Years

INTERPRETED BY

Sebastian Schaub, DVM
Dr. med. vet. DipECVDI

HOSPITAL NAME

Mobile Pet Imaging



REFERRING VET

Meaux

INVOICE

48661

DATE

11-30-21

The information and recommendations provided are based on the images presented by the referring veterinarian. No evaluation can be communicated regarding pathology that was not visible in the image/video clips provided.

Thank you for this referral. If the clinical or image interpretation does not parallel your findings or if I can be of any further assistance please contact me.

Sebastian Schaub, Sebastian Schaub, DVM, Dr. med. vet. DipECVDI
sebast.schaub@gmail.com