



PATIENT

Cava Ramos

SPECIES

Feline

BREED

DSH

SEX

Male

AGE

1Y, 10M

WEIGHT

11lbs

INTERPRETED BY

Sebastian Schaub, DVM
Dr. med. vet.
DipECVDI

IMAGING PERFORMED BY

Mallory Frois

HOSPITAL NAME

The Pet Hospital of
Stratford

REFERRING VET

Dr. Claudia Giuliani,
DVM

INVOICE

72465

DATE

11-3-25

PRESENTING CLINICAL SIGNS

O noted p walking strange this am and did not want to jump on chair. P clawed his way up chair. Per o was normal last night. Indoor only.

Abnormal PE/Chem/CBC/UA Results: limping left hind. Seems painful on extension of left leg.

RADIOGRAPHIC STUDY OF THE PELVIS AND STIFLE JOINTS

A complete set of radiographs of the pelvis and stifle joints is provided for review.

RADIOGRAPHIC FINDINGS

The osseous and surrounding soft tissue structures of the pelvis are within normal limits. Both coxofemoral joints present smooth osseous margins and congruent joint spaces.

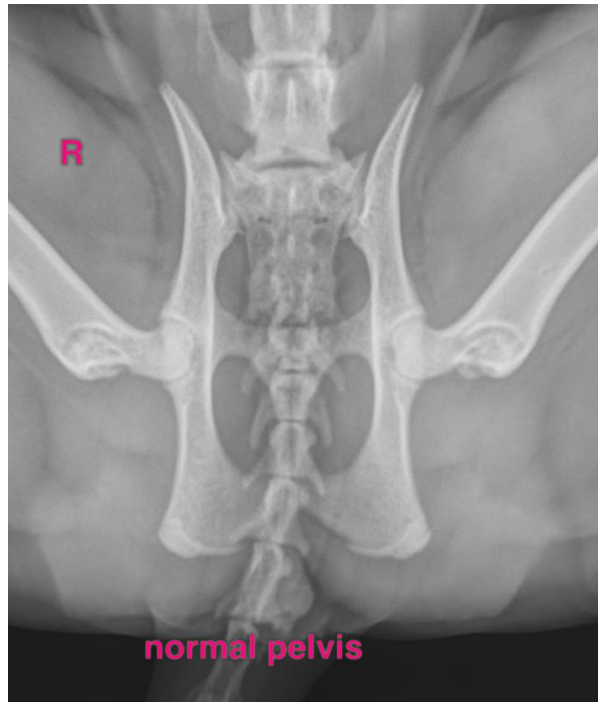
Both stifle joints present smooth margins of the periarticular bones and no sign of an intracapsular soft tissue swelling. The patella of both stifle joints is in situ.

RADIOGRAPHIC DIAGNOSIS

- Normal pelvis
- Normal stifle joints

INTERPRETATION OF THE FINDINGS & FURTHER RECOMMENDATIONS

The radiographic study reveals no abnormalities, there is no evidence of hip dysplasia nor signs of degenerative joint disease of the elbow joints, arthritis nor patellar luxation.





PATIENT

Cava Ramos

SPECIES

Feline

BREED

DSH

SEX

Male

AGE

1Y, 10M

WEIGHT

11lbs

INTERPRETED BY

Sebastian Schaub, DVM
Dr. med. vet.
DipECVDI

IMAGING PERFORMED BY

Mallory Frois

HOSPITAL NAME

The Pet Hospital of
Stratford

REFERRING VET

Dr. Claudia Giuliani,
DVM

INVOICE

72465

DATE

11-3-25

The information and recommendations provided are based on the images presented by the referring veterinarian/sonographer. No evaluation can be communicated regarding pathology that was not visible in the image/video clips provided.

Thank you for this referral. If the clinical or image interpretation does not parallel your findings or if I can be of any further assistance please contact me.

Sebastian Schaub, Sebastian Schaub, DVM, Dr. med. vet. DipECVDI
info@sonopath.com