



PATIENT PRESENTING CLINICAL SIGNS

Nayru SCAT
 Nayru presented Nov. 2/22 for an exam for some breathing issues. Her current foster (Janice) has only had her for ~2 weeks. Nayru has had a few URT infections previously while under SCAT's care and she has been treated with antibiotics 3 times - suspected herpes virus infection. She also has a head tilt to the L - was like that since SCAT got her according to the records. Janice mentioned that after extreme exercise (running and playing in the house), Nayru will make a gagging/gasping sound like she is struggling to breathe and she extends her neck and opens her mouth to breathe. Janice says it sounds terrible and like she is having difficulty breathing. Mild clear nasal discharge and some sneezing. Mild brown ocular discharge as well. She also mentioned that her stool has been more cow patty-like (diarrhea) off and on since she obtained her.

Feline

DSH
 Abnormal PE/Chem/CBC/UA Results: PE: No heart murmur or arrhythmia on auscultation. Mild increase in lung sounds on L side? (no wheezes or crackles). Mild clear nasal discharge. Mild head tilt to the L. No circling or falling to one side. Mentation appears normal. Ears appear clear on exam and pinna/canals not erythematous or inflamed. On otoscopic exam there is some mild brown waxy debris deeper in the canals; tympanic membranes appear to be intact and no obvious masses seen. No further diagnostics performed at this time.

Female Spayed

RADIOGRAPHIC STUDY OF THE THORAX

Radiographs of the thorax in three imaging planes are provided for review.

RADIOGRAPHIC FINDINGS

The surrounding bony structures are within normal limits.

The extrathoracic soft tissues present homogeneous without abnormalities.

The heart is of normal size and shape, there is no evidence of cardiac chamber or vascular enlargement. The pulmonary vasculature is within normal limits.

The mediastinum is mildly widened and the cranioventral aspects of the lung present a mild increased ground glass opacity.

The trachea is normal in diameter and presents the anticipated course. The luminal outline of the trachea is smooth.

The bronchial tree presents with thin walls and tapers uniformly towards the periphery as expected.

The lung parenchyma presents the expected architecture and opacity; the intrapulmonary vascular branching is seen up to the third order lung vessels.

The diaphragm is well delineated with even surface and the expected mild cranial bulging of the diaphragmatic cupola.

RADIOGRAPHIC DIAGNOSIS

- Normal thorax

INTERPRETED BY

Sebastian Schaub, DVM
 Dr. med. vet. DipECVDI

HOSPITAL NAME

Woodridge
 Veterinary Clinic

REFERRING VET

Breanne
 Couperthwaite

INVOICE

54985

DATE

11-3-22



PATIENT

Nayru SCAT

SPECIES

Feline

BREED

DSH

SEX

Female Spayed

AGE

14 Months

INTERPRETED BY

Sebastian Schaub, DVM
Dr. med. vet. DipECVDI

HOSPITAL NAME

Woodridge
Veterinary Clinic

REFERRING VET

Breanne
Couperthwaite

INVOICE

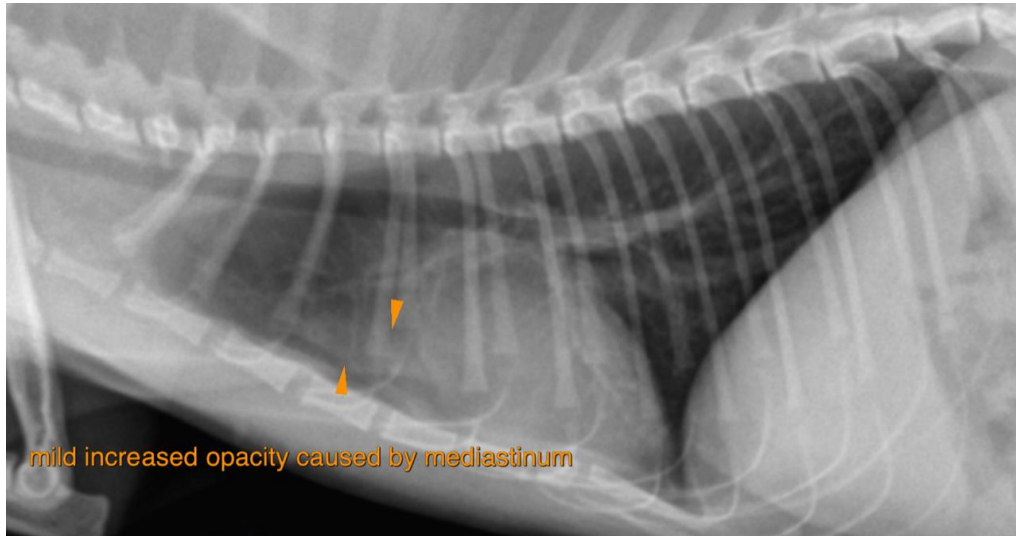
54985

DATE

11-3-22

INTERPRETATION OF THE FINDINGS & FURTHER RECOMMENDATIONS

The radiographic study of the thorax presents without abnormalities. The mild prominent mediastinum is likely a sequela to the thymus. Given the clinical signs, rule out underlying primary upper respiratory tract infection ± possible inflammatory polyp formation.



The information and recommendations provided are based on the images presented by the referring veterinarian/sonographer. No evaluation can be communicated regarding pathology that was not visible in the image/video clips provided.

Thank you for this referral. If the clinical or image interpretation does not parallel your findings or if I can be of any further assistance please contact me.

Sebastian Schaub, Sebastian Schaub, DVM, Dr. med. vet. DipECVDI
sebast.schaub@gmail.com