



PATIENT PRESENTING CLINICAL SIGNS

Jessie Horne History: discomfort on lumbar spine area, more lethargic, not acting herself lately
 Abnormal PE/Chem/CBC/UA Results: delay in proprioception in both hind legs (more so seen on L side), discomfort when palpating lumbar spine after sedation, Jessie was not able to walk on L hind leg

SPECIES

Canine

RADIOGRAPHIC STUDY OF THE LUMBAR SPINE AND STIFLE JOINTS

BREED

Radiographs of the lumbar spine in a lateral and ventrodorsal projection and the stifle joints in a mediolateral projection are provided for review.

Basset Hound

RADIOGRAPHIC FINDINGS

SEX

There is a breed specific chondrodystrophic conformation of the skeletal structures.

Spayed Female

The intervertebral disc spaces L1/L2 and L5/L6 are mildly narrowed. The remainder of the osseous and soft tissue structures of the lumbar spine are within normal limits.

AGE

Both stifle joints present smooth osseous margins and without evidence of intracapsular soft tissue swelling.

6 Years

RADIOGRAPHIC DIAGNOSIS

INTERPRETED BY

- Discopathy L1/L2 and L5/L6
- Normal stifle joints

Sebastian Schaub,
 DVM Dr. med. vet.
 DipECVDI

INTERPRETATION OF THE FINDINGS & FURTHER RECOMMENDATIONS

The narrowed intervertebral disc spaces indicate discopathy that might or might not be associated with compressive myelopathy. Given the clinically appreciated paraparesis, compressive myelopathy should be rule in/out by cross-sectional imaging.

HOSPITAL NAME

Truscott AH

REFERRING VET

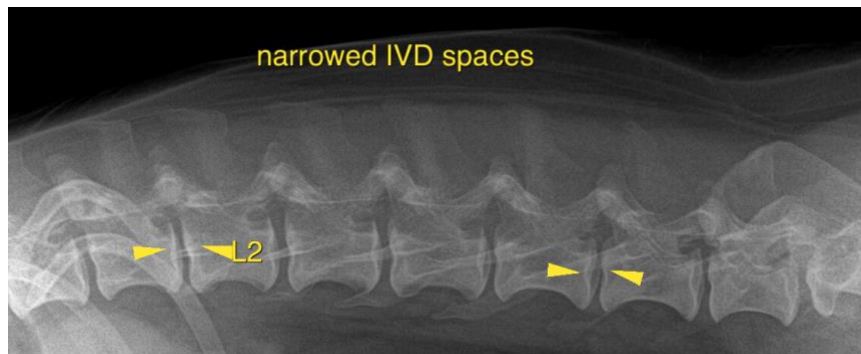
Dr. Medhat Meawad

INVOICE

17986

DATE

11/3/22





PATIENT

Jessie Horne

The information and recommendations provided are based on the images presented by the referring veterinarian/sonographer. No evaluation can be communicated regarding pathology that was not visible in the image/video clips provided.

SPECIES

Canine

Thank you for this referral. If the clinical or image interpretation does not parallel your findings or if I can be of any further assistance please contact me.

BREED

Basset Hound

Sebastian Schaub, Sebastian Schaub, DVM, Dr. med. vet. DipECVDI
sebast.schaub@gmail.com

SEX

Spayed Female

AGE

6 Years

INTERPRETED BY

Sebastian Schaub,
DVM Dr. med. vet.
DipECVDI

HOSPITAL NAME

Truscott AH

REFERRING VET

Dr. Medhat Meawad

INVOICE

17986

DATE

11/3/22