

**PATIENT PRESENTING CLINICAL SIGNS**

Cinnabun Egor Chronic respiratory problems, suspect chronic sinusitis. Pasteurella grown on culture from 2017
Abnormal PE/Chem/CBC/UA Results: Increased RR and RE. Nasal discharge evident.

SPECIES COMPUTED TOMOGRAPHY OF THE SKULL

Lagamorph A high resolution pre- and post-contrast CT study of the skull is provided for review.

COMPUTED TOMOGRAPHIC FINDINGS**BREED**

The pictured parts of the dentition are complete and unremarkable in all jaw quadrants.

Rabbit

Mild destruction of the nasal conchal & turbinate structures bilaterally is appreciated. In the right nasal cavity, rostral to the alveolar crest of triadan 106, a focal intranasal swelling with two small roundish mineralized bodies is seen, measuring 1.1 mm in diameter. The osseous lamella between the swelling and the alveolar crest of triadan 106 cannot be clearly delineated.

SEX**Male**

Both temporomandibular joints present congruent joint spaces with even subchondral bone surfaces and are considered within normal limits.

AGE**9 Years**

The right tympanic bulla is aerated, the mucosal lining is not seen, the bony wall is smooth and thin. In the left tympanic bulla, a small amount of gravity dependent, soft tissue attenuating material is attached to the mucosal lining. The external ear canals are within normal limits.

INTERPRETED BY

Sebastian Schaub, DVM
Dr. med. vet. DipECVDI

COMPUTED TOMOGRAPHIC DIAGNOSIS

- Mild destructive rhinitis
- Suspect small rhinoliths right nasal cavity
- Very mild left sided otitis media

HOSPITAL NAME

Mobile Pet Imaging

INTERPRETATION OF THE FINDINGS & FURTHER RECOMMENDATIONS

The CT findings are consistent with destructive rhinitis – Pasteurella related rhinitis is most common. There is evidence of small rhinoliths in the right nasal cavity. As the osseous lamella of the alveolar crest of triadan 106 cannot be clearly delineated there might be an odontogenic origin of the focal right sided intranasal swelling that might serve as trigger for rhinitis.

REFERRING VET

Meaux

INVOICE

55422

DATE

11-29-22



PATIENT

Cinnabun Egor

SPECIES

Lagamorph

BREED

Rabbit

SEX

Male

AGE

9 Years

INTERPRETED BY

Sebastian Schaub, DVM
Dr. med. vet. DipECVDI

HOSPITAL NAME

Mobile Pet Imaging

REFERRING VET

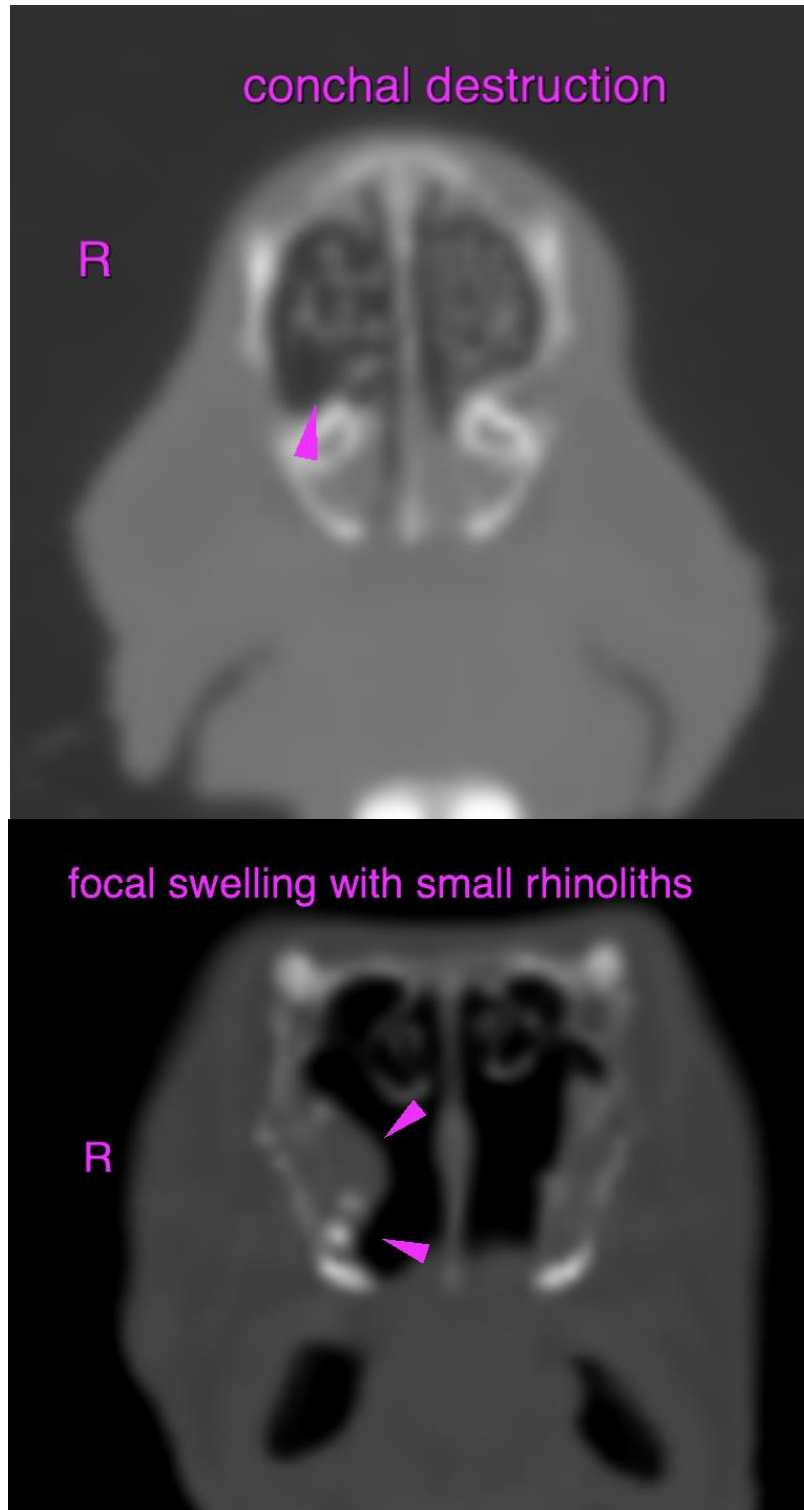
Meaux

INVOICE

55422

DATE

11-29-22





PATIENT

Cinnabun Egor

SPECIES

Lagamorph

BREED

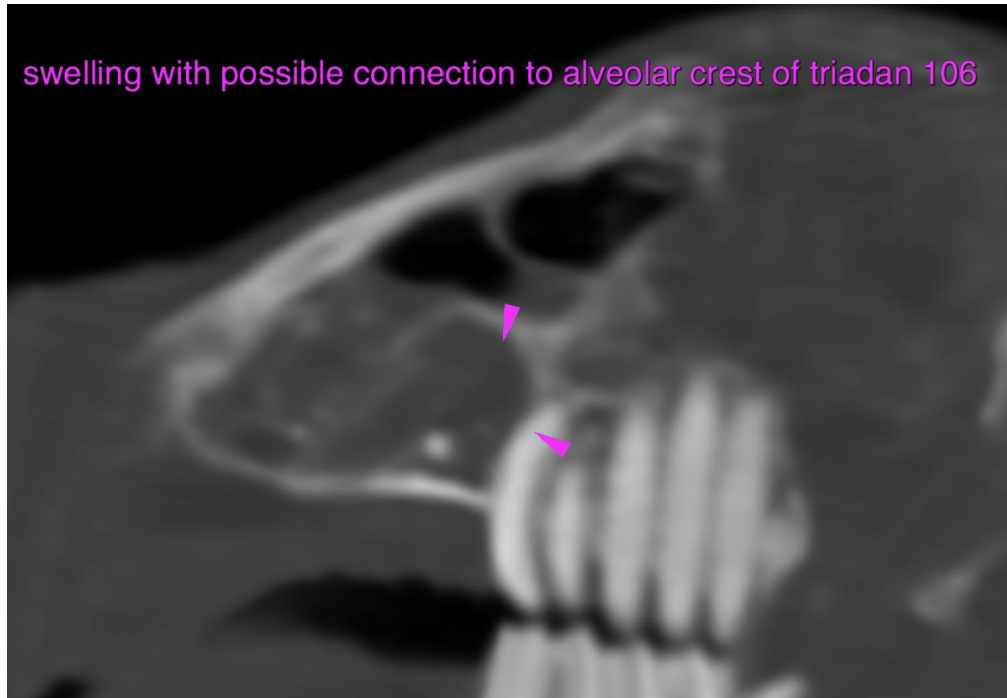
Rabbit

SEX

Male

AGE

9 Years



INTERPRETED BY

Sebastian Schaub, DVM
Dr. med. vet. DipECVDI

The information and recommendations provided are based on the images presented by the referring veterinarian/sonographer. No evaluation can be communicated regarding pathology that was not visible in the image/video clips provided.

HOSPITAL NAME

Mobile Pet Imaging

Thank you for this referral. If the clinical or image interpretation does not parallel your findings or if I can be of any further assistance please contact me.

Sebastian Schaub, Sebastian Schaub, DVM, Dr. med. vet. DipECVDI
sebast.schaub@gmail.com

REFERRING VET

Meaux

INVOICE

55422

DATE

11-29-22