**PATIENT**

Bader Adam

SPECIES

Canine

BREED

Golden Retriever

SEX

MN

AGE

10 Months

INTERPRETED BYSebastian Schaub, DVM
Dr. med. vet. DipECVDI**HOSPITAL NAME**Gentle Doctor Animal
Hospital**REFERRING VET**

Dr. Rotthaus

INVOICE

55435

DATE

11-29-22

PRESENTING CLINICAL SIGNS

Bader presented for sudden onset lameness of right forearm that started 10 days ago. Weight bearing lameness in room. Dog has extensive travel history and has hiked with owners in Colorado, North Carolina and Tennessee. Has been on simparica trio monthly. Ehrlichia, HW, anaplasma, and Lyme negative. Owner did not initially report any shifting leg lameness, however, on recheck call, did report that it is possible he occasionally limps on his hind limbs. Dx: Elbow dysplasia, panosteitis, tick borne. No improvement on gabapentin and Rimadyl. Otherwise, eating, drinking and acting normally.

RADIOGRAPHIC STUDY OF THE ELBOW JOINTS

Radiographs of the elbow joints in two orthogonal imaging planes are provided for review.

RADIOGRAPHIC FINDINGS

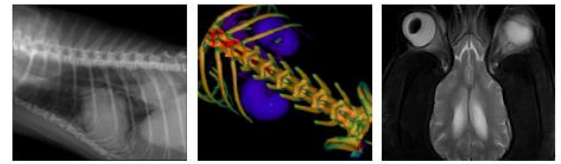
Both elbow joints present smooth osseous margins. At the base of the medial coronoid process of both elbow joints, a moderate sclerosis of the ulna is appreciated. The cranial contour of the medial coronoid process of both elbow joints is ill-defined and blurred. The soft tissue structures surrounding the elbow joints are within normal limits.

RADIOGRAPHIC DIAGNOSIS

- Suspect coronoid disease elbow joints bilaterally

INTERPRETATION OF THE FINDINGS & FURTHER RECOMMENDATIONS

The ill-defined contour of the medial coronoid process and the accompanying sclerosis at the base of the medial coronoid process, is highly concerning for underlying coronoid disease – a potential source for the front limb lameness. Check clinically if pain can be elicited by pressure on the medial coronoid process supporting the diagnosis. Workup can be complemented by CT study of the elbow joints for potential surgical planning.



PATIENT

Bader Adam

SPECIES

Canine

BREED

Golden Retriever

SEX

MN

AGE

10 Months

INTERPRETED BY

Sebastian Schaub, DVM
Dr. med. vet. DipECVDI

HOSPITAL NAME

Gentle Doctor Animal
Hospital

REFERRING VET

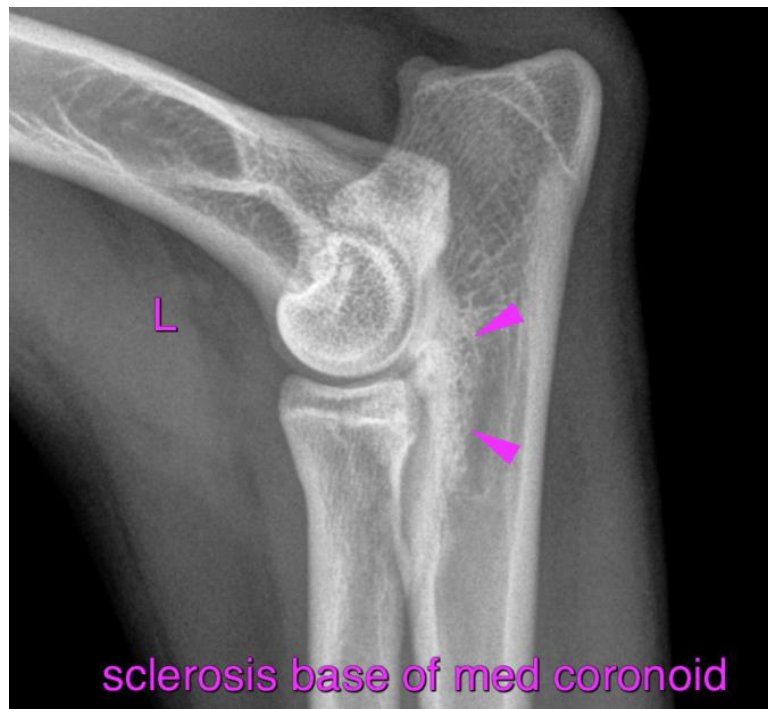
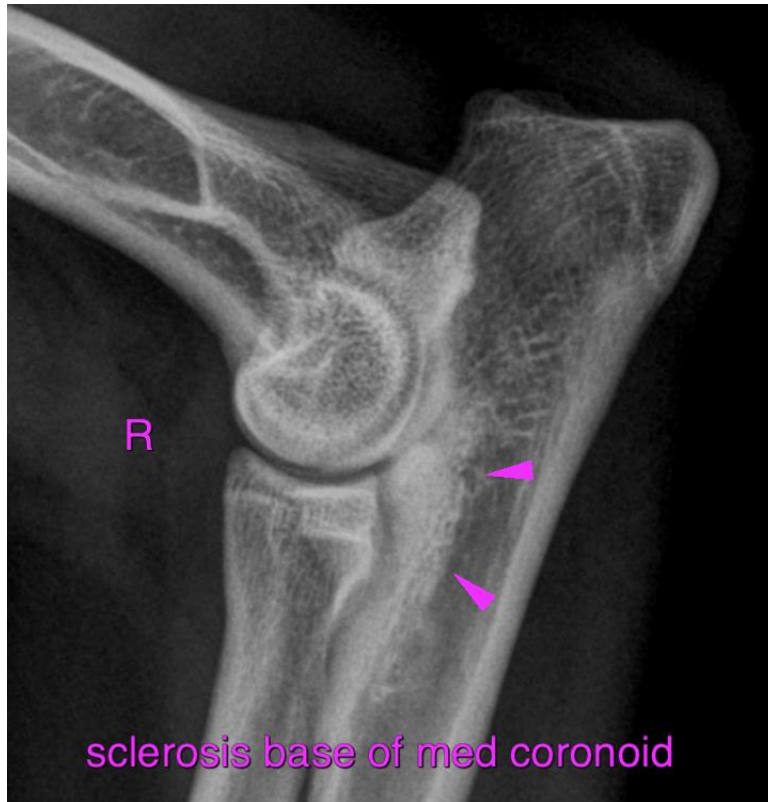
Dr. Rotthaus

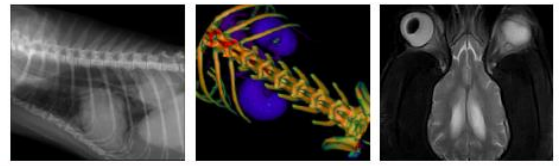
INVOICE

55435

DATE

11-29-22





PATIENT

Bader Adam

SPECIES

Canine

The information and recommendations provided are based on the images presented by the referring veterinarian/sonographer. No evaluation can be communicated regarding pathology that was not visible in the image/video clips provided.

BREED

Golden Retriever

Thank you for this referral. If the clinical or image interpretation does not parallel your findings or if I can be of any further assistance please contact me.

Sebastian Schaub, Sebastian Schaub, DVM, Dr. med. vet. DipECVDI
sebast.schaub@gmail.com

SEX

MN

AGE

10 Months

INTERPRETED BY

Sebastian Schaub, DVM
Dr. med. vet. DipECVDI

HOSPITAL NAME

Gentle Doctor Animal
Hospital

REFERRING VET

Dr. Rotthaus

INVOICE

55435

DATE

11-29-22