



**PATIENT**

Zoe Tripodi

**PRESENTING CLINICAL SIGNS**

Zoe had F.B. removal surgery 5 days ago from the colon. After surgery she's eating, drinking & urinating normally. Owner does not sure about the bowel movement as he has another cat at home & was thinking she's constipated.

**SPECIES**

Feline

Abnormal PE/Chem/CBC/UA Results: Low ALKP B.C.S: 2.5/5

**RADIOGRAPHIC STUDY OF THE ABDOMEN**

Radiographs of the abdomen in three imaging planes are provided for review.

**BREED**

Domestic Shorthair

**RADIOGRAPHIC FINDINGS**

The patient presents with a lean body condition and the lack of peritoneal fat is decreasing the serosal detail.

**SEX**

Spayed Female

There is a moderate amount of free peritoneal gas. Multiple gas bubbles are seen in the subcutaneous tissue along the ventral abdominal wall.

The surrounding bony structures are within normal limits.

**AGE**

2 Years

The liver is appropriate in position, size and presents uniform opacity.

The splenic head is in the anticipated position and within normal limits for size and opacity.

**INTERPRETED BY**

Sebastian Schaub, DVM  
Dr. med. vet. DipECVDI

Both kidneys are seen and present with normal size, shape, delineation and opacity. The urinary bladder is in its anticipated position. No radiopaque calculi are noted throughout the upper and lower urinary tract.

The stomach is in its anticipated position and presents normal content.

**HOSPITAL NAME**

Creditview-Eglinton  
Animal Hospital

The small intestinal loops are of even diameter and non-dilated, a small amount of gas is seen within the small intestinal loops and considered within normal limits.

The colon is seen in the expected position and presents with appropriate content.

**REFERRING VET**

Elhamy Ghobrial

**RADIOGRAPHIC DIAGNOSIS**

- Current state five days post laparotomy with secondary pneumoperitoneum

**INVOICE**

48650

**INTERPRETATION OF THE FINDINGS & FURTHER RECOMMENDATIONS**

The current radiographic study presents without signs for constipation, the colon contains only a mild amount of fecal material. The pneumoperitoneum is considered as a normal postoperative finding.

**DATE**

11-29-21



**PATIENT**

Zoe Tripodi

**SPECIES**

Feline

**BREED**

Domestic Shorthair

**SEX**

Spayed Female

**AGE**

2 Years

**INTERPRETED BY**

Sebastian Schaub, DVM  
Dr. med. vet. DipECVDI

**HOSPITAL NAME**

Creditview-Eglinton  
Animal Hospital

**REFERRING VET**

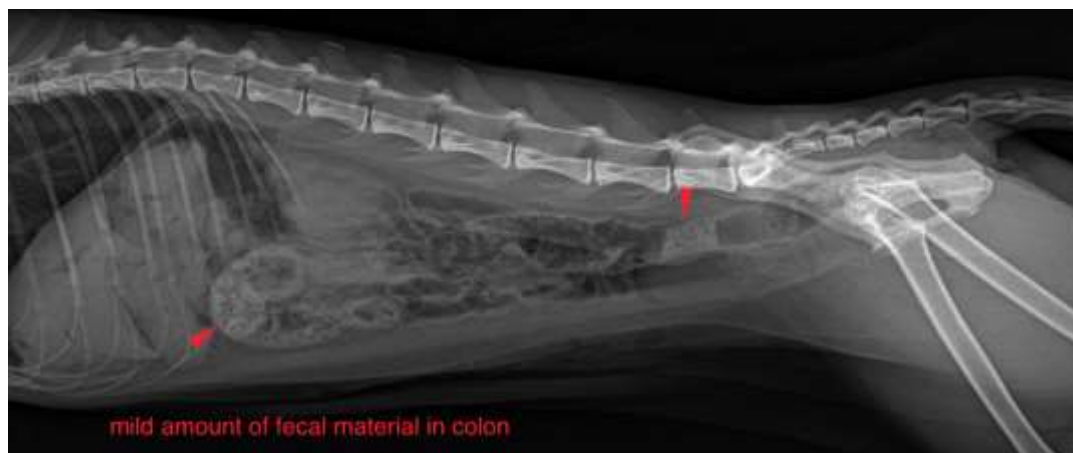
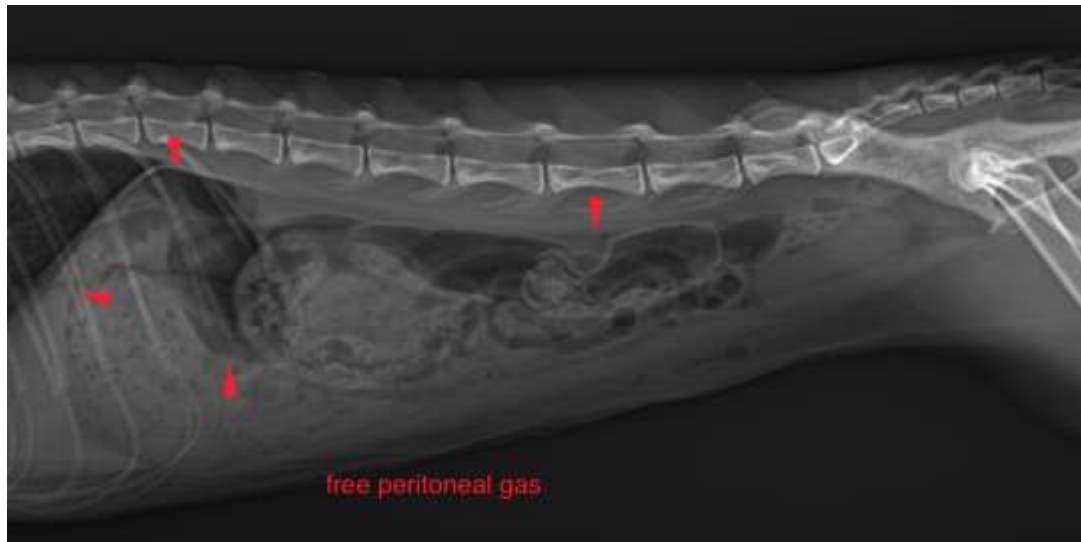Elhamy Ghobrial

**INVOICE**

48650

**DATE**

11-29-21



The information and recommendations provided are based on the images presented by the referring veterinarian. No evaluation can be communicated regarding pathology that was not visible in the image/video clips provided.

Thank you for this referral. If the clinical or image interpretation does not parallel your findings or if I can be of any further assistance please contact me.

**Sebastian Schaub**, Sebastian Schaub, DVM, Dr. med. vet. DipECVDI  
sebast.schaub@gmail.com