

**PATIENT**

Lucky Giurgea

PRESENTING CLINICAL SIGNS

A few fine crackles heard from lungs. more on L chest. Cannot elicit cough with tracheal palp. Grade II-III systolic murmur heard on R chest, barely audible on L chest.

SPECIES

Canine

RADIOGRAPHIC STUDY OF THE THORAX

Radiographs of the thorax in three imaging planes are provided for review.

BREED

Shih Tzu x

RADIOGRAPHIC FINDINGS

The surrounding bony structures are within normal limits.

The extrathoracic soft tissues present homogeneous without abnormalities.

SEX

MN

The heart is of normal size and shape, there is no evidence of cardiac chamber or vascular enlargement. The pulmonary vasculature is within normal limits.

The cranial mediastinum presents the expected soft tissue opacity. The mediastinal width is less than twice the width of the vertebral column at the same level.

AGE

13 Years

The trachea is normal in diameter and presents the anticipated course. The luminal outline of the trachea is smooth.

INTERPRETED BY

Sebastian Schaub, DVM
Dr. med. vet. DipECVDI

The bronchial tree presents with thin walls and tapers uniformly towards the periphery as expected.

The lung parenchyma presents the expected architecture and opacity; the intrapulmonary vascular branching is seen up to the third order lung vessels.

HOSPITAL NAME

Sylvan Lake
Veterinary Clinic

The diaphragm is well delineated with even surface and the expected mild cranial bulging of the diaphragmatic cupola.

RADIOGRAPHIC DIAGNOSIS

- Normal thorax

REFERRING VET

Dr. Marv Mattson

INTERPRETATION OF THE FINDINGS & FURTHER RECOMMENDATIONS

The radiographic study of the thorax presents without abnormalities. The fine crackles heard, might be a sequela to mild pulmonary fibrosis, presenting without radiographic changes of the lung parenchyma. Consider follow up radiographs if findings from the auscultation deteriorate or clinical signs such as dyspnea or cough develop.

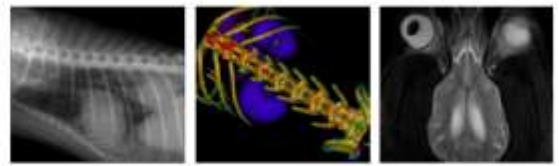
INVOICE

48639

TECHNICAL COMMENTS**DATE**

11-29-21

Human fingers are seen in the primary beam, please consider radiation safety guidelines!



PATIENT

Lucky Giurgea

The information and recommendations provided are based on the images presented by the referring veterinarian. No evaluation can be communicated regarding pathology that was not visible in the image/video clips provided.

SPECIES

Canine

Thank you for this referral. If the clinical or image interpretation does not parallel your findings or if I can be of any further assistance please contact me.

Sebastian Schaub, Sebastian Schaub, DVM, Dr. med. vet. DipECVDI
sebast.schaub@gmail.com

BREED

Shih Tzu x

SEX

MN

AGE

13 Years

INTERPRETED BY

Sebastian Schaub, DVM
Dr. med. vet. DipECVDI

HOSPITAL NAME

Sylvan Lake
Veterinary Clinic

REFERRING VET

Dr. Marv Mattson

INVOICE

48639

DATE

11-29-21