



PATIENT PRESENTING CLINICAL SIGNS

Gryff Moody in for dental owner concerned about breathing, getting worse, NSF on physical exam
Abnormal PE/Chem/CBC/UA Results: Normal BW

SPECIES RADIOGRAPHIC STUDY OF THE THORAX

Canine Radiographs of the thorax in three imaging planes are provided for review.

RADIOGRAPHIC FINDINGS

BREED

Yorkshire Terrier

The surrounding bony structures are within normal limits.

The extrathoracic soft tissues present homogeneous without abnormalities.

SEX

MN

The heart is of normal size and shape, there is no evidence of cardiac chamber or vascular enlargement. The pulmonary vasculature is within normal limits.

The cranial mediastinum presents the expected soft tissue opacity. The mediastinal width is less than twice the width of the vertebral column at the same level.

AGE

8 Years

The cervical tracheal segment presents dynamic moderate narrowing of the height, between the right & left lateral projection of the thorax..

INTERPRETED BY

Sebastian Schaub, DVM
Dr. med. vet. DipECVDI

The bronchial tree presents with thin walls and tapers uniformly towards the periphery as expected.

The lung parenchyma presents the expected architecture and opacity; the intrapulmonary vascular branching is seen up to the third order lung vessels.

HOSPITAL NAME

Sylvan Lake
Veterinary Clinic

The diaphragm is well delineated with even surface and the expected mild cranial bulging of the diaphragmatic cupola.

RADIOGRAPHIC DIAGNOSIS

- Dynamic tracheal collapse cervical segment
- Normal thorax

REFERRING VET

Dr. Andrew Hodges

INTERPRETATION OF THE FINDINGS & FURTHER RECOMMENDATIONS

Depending on the clinical signs the tracheal collapse might causes phases of dyspnea or cough. Tracheoscopy might be used for further grading of tracheal collapse and rule in/out accompanying bronchial collapse. A BAL can be used to check for inflammatory lower airway disease.

INVOICE

48636

The lung parenchyma presents without abnormalities.

DATE

11-29-21



PATIENT

Gryff Moody

SPECIES

Canine

BREED

Yorkshire Terrier

SEX

MN

AGE

8 Years

INTERPRETED BY

Sebastian Schaub, DVM
Dr. med. vet. DipECVDI

HOSPITAL NAME

Sylvan Lake
Veterinary Clinic

REFERRING VET

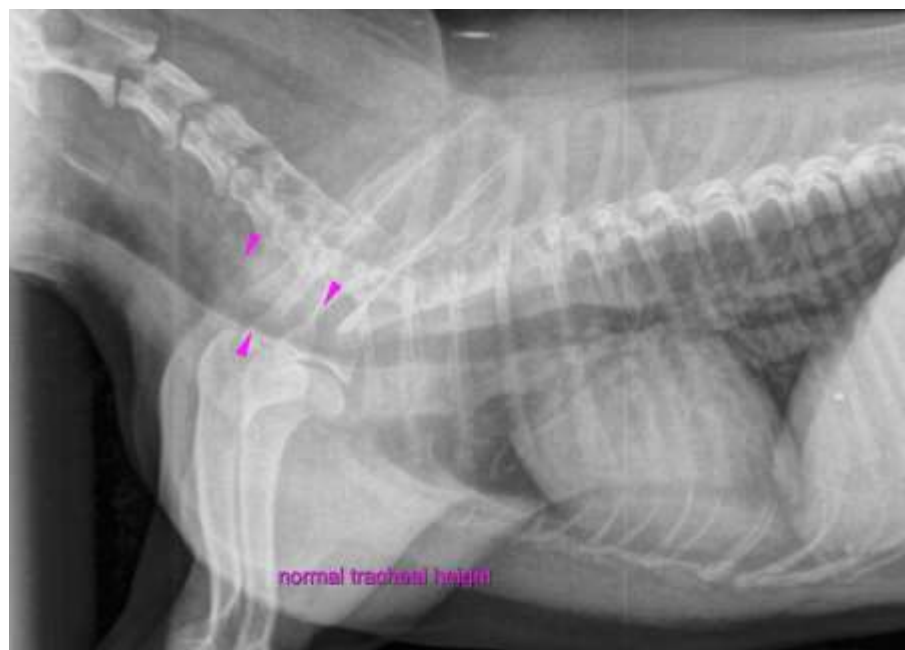
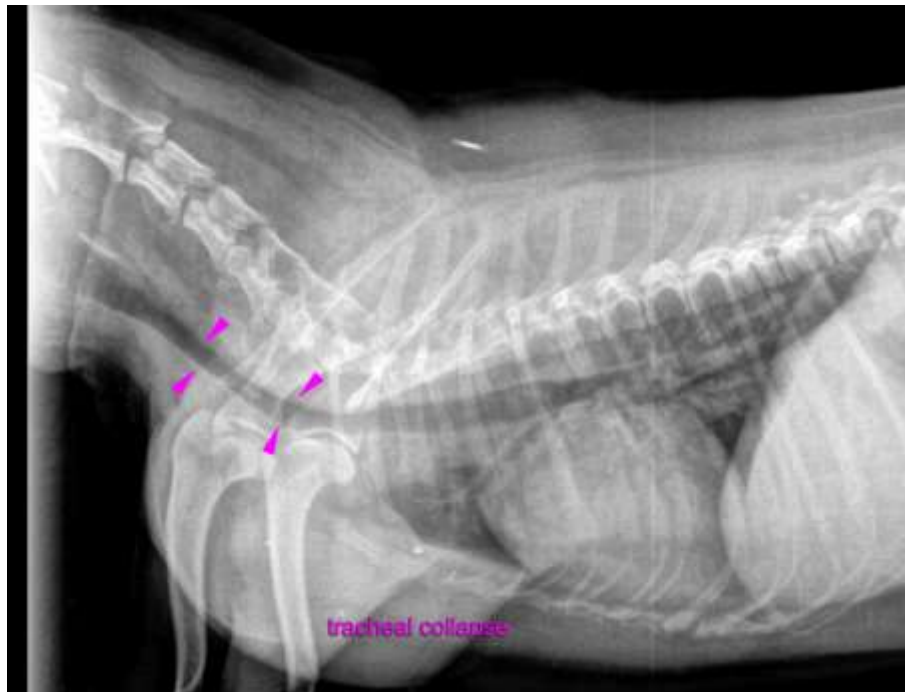
Dr. Andrew Hodges

INVOICE

48636

DATE

11-29-21





PATIENT

Gryff Moody

The information and recommendations provided are based on the images presented by the referring veterinarian. No evaluation can be communicated regarding pathology that was not visible in the image/video clips provided.

SPECIES

Canine

Thank you for this referral. If the clinical or image interpretation does not parallel your findings or if I can be of any further assistance please contact me.

Sebastian Schaub, Sebastian Schaub, DVM, Dr. med. vet. DipECVDI
sebast.schaub@gmail.com

BREED

Yorkshire Terrier

SEX

MN

AGE

8 Years

INTERPRETED BY

Sebastian Schaub, DVM
Dr. med. vet. DipECVDI

HOSPITAL NAME

Sylvan Lake
Veterinary Clinic

REFERRING VET

Dr. Andrew Hodges

INVOICE

48636

DATE

11-29-21