

## PATIENT

Nova Clarke

## SPECIES

Canine

## BREED

Staffordshire Bull Terrier

## SEX

Female

## AGE

3

## WEIGHT

25

## INTERPRETED BY

Sebastian Schaub, DVM  
Dr. med. vet. DipECVCI

## IMAGING PERFORMED BY

Hollie Sharp

## HOSPITAL NAME

Animal Trust Ellesmere Port

## REFERRING VET

Dr. Dylan Payne

## INVOICE

35706

## DATE

11/28/25

## PRESENTING CLINICAL SIGNS

History: Lameness on Left fore, is worse first thing in morning following rest. Ortho surgeon suspects Elbow pain.

## COMPUTED TOMOGRAPHIC STUDY OF THE FRONT LIMBS

A high-resolution plain CT study of the front limbs is provided for review.

## COMPUTED TOMOGRAPHIC FINDINGS

Both shoulder joints present smooth margins of the periarticular bones and the surrounding soft tissue structures are within normal limits.

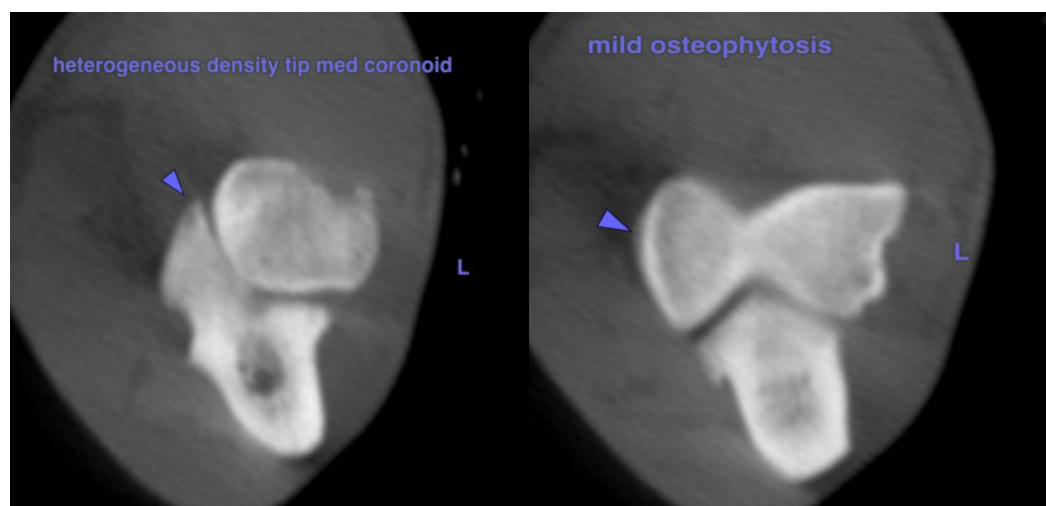
The periarticular bones of both elbow joints present mild osteophyte new bone formation. The medial coronoid process of both elbow joints has a mild irregular conformation and heterogeneous density, L>R. The surrounding soft tissue structures of the elbow joints are unremarkable.

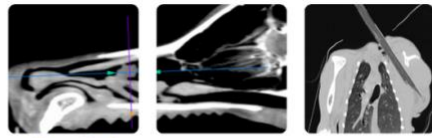
## COMPUTED TOMOGRAPHIC DIAGNOSIS

- Coronoid disease elbow joint bilaterally
- Mild osteoarthritis both elbow joints
- Normal shoulder joints

## INTERPRETATION OF THE FINDINGS & FURTHER RECOMMENDATIONS

The CT study is supporting the diagnosis of bilateral elbow dysplasia and secondary mild degenerative joint disease of both elbow joints. Arthroscopy/arthrotomy would be ideal to revise the elbow joints and remove the osseous fragment/nonvital tip of the medial coronoid process to avoid further damage.





## PATIENT

Nova Clarke

## SPECIES

Canine

## BREED

Staffordshire Bull  
Terrier

## SEX

Female

## AGE

3

## WEIGHT

25

## INTERPRETED BY

Sebastian Schaub, DVM  
Dr. med. vet. DipECVDI

## IMAGING PERFORMED BY

Hollie Sharp

## HOSPITAL NAME

Animal Trust Ellesmere  
Port

## REFERRING VET

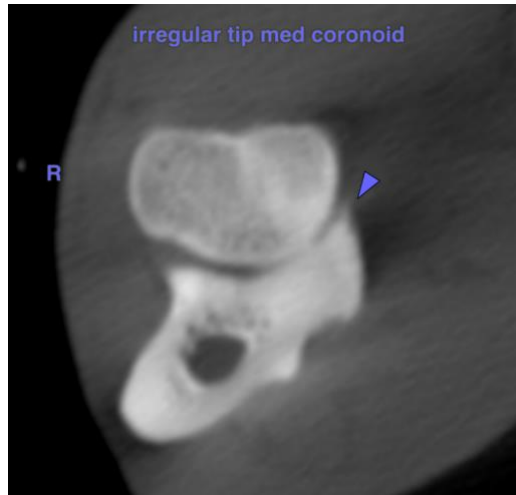
Dr. Dylan Payne

## INVOICE

35706

## DATE

11/28/25



**The information and recommendations provided are based on the images presented by the referring veterinarian/sonographer. No evaluation can be communicated regarding pathology that was not visible in the image/video clips provided.**

Thank you for this referral. If the clinical or image interpretation does not parallel your findings or if I can be of any further assistance please contact me.

**Sebastian Schaub**, DVM, Dr. med. vet. DipECVDI  
[info@sonopath.com](mailto:info@sonopath.com)