



PATIENT

Gremlin Hulley

SPECIES

Feline

BREED

Domestic Shorthair

SEX

Male

AGE

1

WEIGHT

0.88

INTERPRETED BY

Sebastian Schaub, DVM
Dr. med. vet. DipECVDI

IMAGING PERFORMED BY

Hollie Sharp

HOSPITAL NAME

Animal Trust Ellesmere
Port

REFERRING VET

Dr. Amber Mahon

INVOICE

35708

DATE

11/28/25

PRESENTING CLINICAL SIGNS

History: Been in owners possession 1 month. Taken on from someone who was struggling to care for him. Chronic diarrhea and reduced appetite. No vomiting. Bright demeanor. Up to date flea/ worm treatment but not vaccinated or neutered. Severely stunted growth Emaciated - BCS 1/9 Mucous membranes very very pale pink Crusty nasal discharge Chest ausc NAD Abdo palp NAD Diarrhea around back end.

COMPUTED TOMOGRAPHIC STUDY OF THE SKULL, THORAX AND ABDOMEN

A high resolution pre- and post-contrast CT study of the skull and abdomen and a post-contrast CT study of the thorax is provided for review.

COMPUTED TOMOGRAPHIC FINDINGS

The body condition score is 1-2/9.

Skull

The pictured parts of the dentition are complete and unremarkable in all jaw quadrants.

The nasal cavity presents the expected aerated spaces between thin & even conchae and turbinates with smooth mucosal lining.

Both temporomandibular joints present congruent joint spaces with even subchondral bone surfaces and are considered within normal limits.

Both tympanic bullae are aerated, the mucosal lining is not seen, the bony wall is smooth and thin. The external ear canals are within normal limits.

The brain presents no deviation from normal anatomy and symmetry. The brain parenchyma is homogeneous and within normal limits for attenuation and distribution of contrast enhancement. The ventricular system is non-dilated and symmetric.

The submandibular and medial retropharyngeal lymph nodes are small and elongated with a normal short-to-long-axis-ratio is < 0.5, the attenuation and contrast enhancement pattern is uniform.

Thorax

The bony and surrounding soft tissue structures are within normal limits.

The sternal, cranial mediastinal and tracheobronchial lymph nodes are small elongated with a normal short-to-long-axis-ratio is < 0.5, the attenuation and contrast enhancement pattern is uniform and considered within normal limits.

The cardiovascular structures including the pulmonary vasculature are within normal limits.

The bronchial tree presents with regular branching and tapers uniformly towards the periphery as expected, the bronchial walls are thin and smooth. The bronchus-to-artery ratio is within normal limits.

The lung parenchyma presents the expected architecture and attenuation behavior.

The esophagus is generalized mild to moderately distended by gas.



PATIENT

Gremlin Hulley

SPECIES

Feline

BREED

Domestic Shorthair

SEX

Male

AGE

1

WEIGHT

0.88

INTERPRETED BY

Sebastian Schaub, DVM
Dr. med. vet. DipECVDI

IMAGING PERFORMED BY

Hollie Sharp

HOSPITAL NAME

Animal Trust Ellesmere
Port

REFERRING VET

Dr. Amber Mahon

INVOICE

35708

DATE

11/28/25

Abdomen

The abdominal detail is generalized decreased due to the lack of peritoneal fat.

Both kidneys present within normal limits for size, shape and organ architecture. After contrast administration a bilaterally symmetric and uniform nephro- and pyelogram is noted.

The adrenal glands are within normal limits for size, shape and organ architecture.

Both liver and spleen present with normal shape, even surface, uniformly attenuating parenchyma and homogeneous contrast enhancement, unremarkable.

The position, delineation, wall and content of the gastrointestinal tract are considered within normal limits throughout.

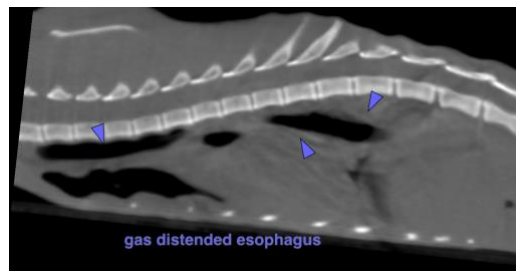
The bony and surrounding soft tissue structures reveal no abnormalities.

COMPUTED TOMOGRAPHIC DIAGNOSIS

- Emaciation
- Generalized gas distended esophagus

INTERPRETATION OF THE FINDINGS & FURTHER RECOMMENDATIONS

The CT study reveals no specific abnormalities that do explain the intestinal clinical signs and emaciation. The gas distended esophagus can be a sequela to general anesthesia – as there is no history of vomiting/regurgitation the odds for megaesophagus are low. Be aware that evaluation of the abdominal structures is limited by the lack of peritoneal fat, but no overt abnormalities are appreciated. Complementing workup by an abdominal ultrasound examination would be beneficial for assessment of the wall of the gastrointestinal tract.



The information and recommendations provided are based on the images presented by the referring veterinarian/sonographer. No evaluation can be communicated regarding pathology that was not visible in the image/video clips provided.

Thank you for this referral. If the clinical or image interpretation does not parallel your findings or if I can be of any further assistance please contact me.

Sebastian Schaub, DVM, Dr. med. vet. DipECVDI
info@sonopath.com