

**PATIENT**

Little Bit Williams

**SPECIES**

Canine

**BREED**

Mixed

**SEX**

FS

**AGE**

12 Years, 10 Months

**INTERPRETED BY**Sebastian Schaub, DVM  
Dr. med. vet. DipECVDI**HOSPITAL NAME**Healing Spirit Animal  
Wellness**REFERRING VET**

Sarah Green

**INVOICE**

55382

**DATE**

11-27-22

**PRESENTING CLINICAL SIGNS**

Diffuse SQ swelling over the left antebrachium initially evaluated 11 months ago. FNA performed at that time was consistent with a lipoma. Suspected to be causing some discomfort. Imaging performed to evaluate surgical options.

Abnormal PE/Chem/CBC/UA Results: Diffuse, poorly defined SQ mass involving the left antebrachium. Ambulatory on all limbs without evident lameness.

**COMPUTED TOMOGRAPHY OF THE LEFT ANTEBRACHIUM**

A high resolution pre- and post-contrast CT study of the left antebrachium is provided for review.

**COMPUTED TOMOGRAPHIC FINDINGS**

At the caudomedial aspect of the left antebrachium, interspersed between the muscle bellies of the flexor muscles, a well-defined fat issue attenuating mass is extending from the level of the elbow joint distally up to the carpal joint. The fat attenuating mass is splaying the muscle bellies of the flexor muscles. The fat-attenuating intermuscular mass is measuring approximately 4.2 x 3.1 x 12.5 cm in size – the most proximal aspect of the fat-attenuating mass is cropped by the field of view. The osseous structures of the included parts of the antebrachium are within normal limits.

**COMPUTED TOMOGRAPHIC DIAGNOSIS**

- Intermuscular lipoma between flexor muscles left antebrachium

**INTERPRETATION OF THE FINDINGS & FURTHER RECOMMENDATIONS**

The clinically appreciated mass is consistent with an intermuscular lipoma, the margins of the mass appear well-defined without overt signs of infiltration of the muscle bellies and surgical excision of the mass can be tried. Be aware of the ulnar nerve entering the proximal aspect of the flexor muscles, likely being in contact with the lipoma.



**PATIENT**

Little Bit Williams

**SPECIES**

Canine

**BREED**

Mixed

**SEX**

FS

**AGE**

12 Years, 10 Months

**INTERPRETED BY**

Sebastian Schaub, DVM  
Dr. med. vet. DipECVDI

**HOSPITAL NAME**

Healing Spirit Animal  
Wellness

**REFERRING VET**

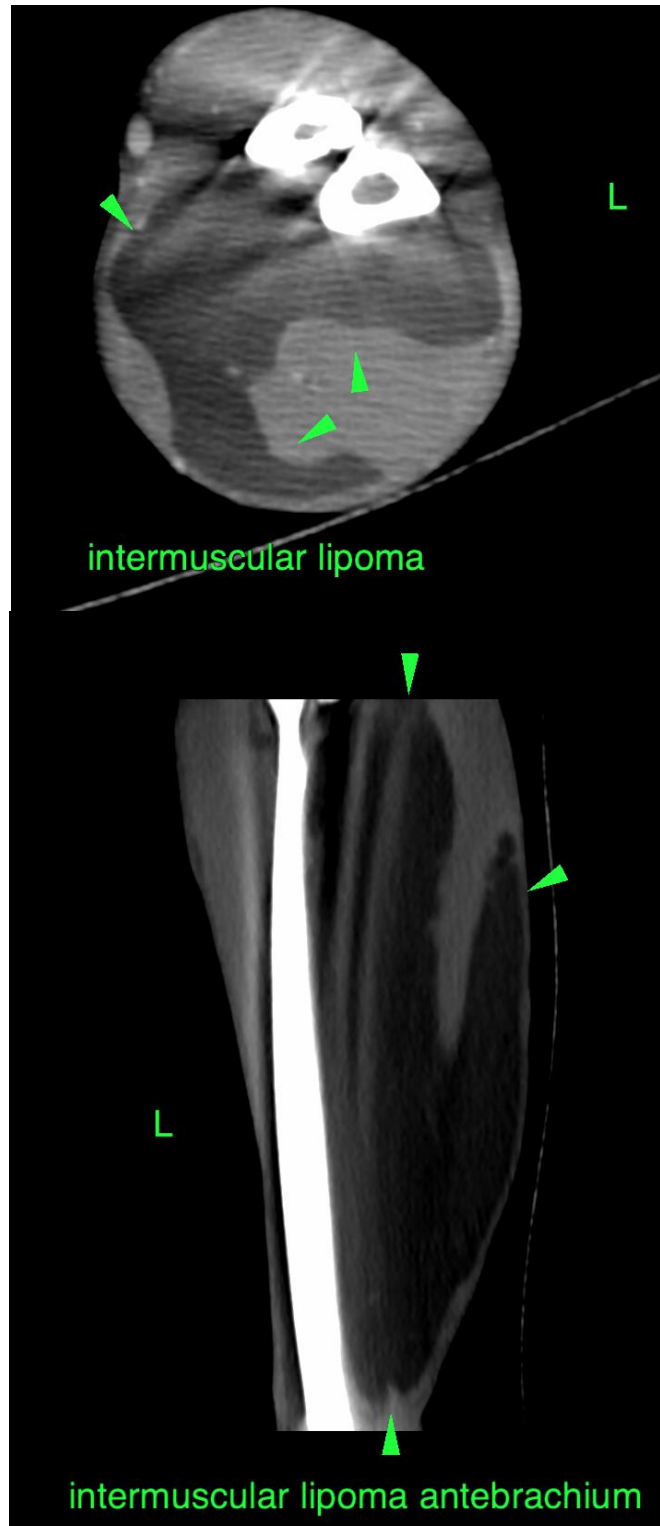
Sarah Green

**INVOICE**

55382

**DATE**

11-27-22





**PATIENT**

Little Bit Williams

**SPECIES**

Canine

**BREED**

Mixed

**SEX**

FS

**AGE**

12 Years, 10 Months

**INTERPRETED BY**

Sebastian Schaub, DVM  
Dr. med. vet. DipECVDI

**HOSPITAL NAME**

Healing Spirit Animal  
Wellness

**REFERRING VET**

Sarah Green

**INVOICE**

55382

**DATE**

11-27-22

The information and recommendations provided are based on the images presented by the referring veterinarian/sonographer. No evaluation can be communicated regarding pathology that was not visible in the image/video clips provided.

Thank you for this referral. If the clinical or image interpretation does not parallel your findings or if I can be of any further assistance please contact me.

**Sebastian Schaub**, Sebastian Schaub, DVM, Dr. med. vet. DipECVDI  
sebast.schaub@gmail.com